

Potential Test of Nephropathy *Sonchus arvensis* L. Leaves on Male Rats (*Rattus norvegicus*) Diabetes Mellitus

Joni Tandji*, I Nyoman Edi Sutrisna, Mentari Pratiwi, Tien Wahyu Handayani

Joni Tandji*, I Nyoman Edi
Sutrisna, Mentari Pratiwi, Tien
Wahyu Handayani

College of pharmaceutical sciences
Pelita Mas Palu, Central Sulawesi 94111,
INDONESIA.

Correspondence

Joni Tandji

College of pharmaceutical sciences
Pelita Mas Palu, Central Sulawesi 94111,
INDONESIA.

E-mail: jonitandji757@yahoo.com

History

- Submission Date: 21-04-2020;
- Review completed: 28-05-2020;
- Accepted Date: 10-06-2020.

DOI : 10.5530/pj.2020.12.158

Article Available online

<http://www.phcogj.com/v12/i5>

Copyright

© 2020 Phcogj.Com. This is an open-access article distributed under the terms of the Creative Commons Attribution 4.0 International license.

ABSTRACT

This study aims to determine the type of secondary metabolites compounds of the ethanol *Sonchus arvensis* L leaves extract, the effect of ethanol *Sonchus arvensis* L leaves extracts the levels of blood glucose and a histopathology picture male white rat induced by streptozotocin. This study used 30 males white rats which were divided into 6 groups, namely the control of normal, negative control, positive control, doses of 200, 300 and 400 mg/kg BW. Results of the study showed that the ethanol *Sonchus arvensis* L. leaves extracts contained compounds of alkaloids, flavonoids, phenols, saponins and tannins. *Sonchus arvensis* L ethanol extract at a dose of 300 mg/kg BW is an effective dose in reducing blood glucose levels with an average value of decreasing blood glucose levels 101.6 mg / dL and has an effect on the regeneration of renal tubular cells with an effective dose is 300 mg / kg body weight with an average damage value of 0.28.

Key Words: Leaf *Sonchus arvensis* L, Diabetes, Renal, Tubular.

INTRODUCTION

Many traditional plant treatments for diabetes are used throughout the world but most of the evidence for their beneficial effects is anecdotal. After the introduction of insulin therapy, the use of traditional treatment for diabetes greatly declined, although some traditional practices are continued for prophylactic purpose and adjuncts to conventional therapy. In some societies, there is a strong desire to use herbs or plants for treatment, due to fewer side effects, easier consumption or availability. However very few of the traditional treatments for diabetes have received scientific or medical scrutiny and several have been shown to assist glycemic control in non-insulin dependent form of diabetes. Plants may act on blood glucose through a different mechanism, some of them may have insulin-like substances.¹

Diabetes mellitus causes high morbidity and mortality, mainly due to vascular complications. It can occur because of the increased free radical formation through glucose metabolism as autooxidise of glucose, metabolism of methylglyoxal formation, and Oxidative Phosphorylation. One type of highly reactive free radicals is the hydroxyl radical. The hydroxyl radical is highly toxic because of its ability to diffuse into the transfers subsequently reacting with the lipid membrane to produce the malondialdehyde (MDA) product. Malondialdehyde is the last result of lipid peroxidation that is used as a parameter of oxidative stress levels and the risk of complications in diabetes mellitus. Besides, free radicals are also reactive ROS (Reactive oxygen species) that may cause DNA oxidation producing 8 hydroxydeoxyguanosins.²

The mechanism of action of STZ to induce diabetes is its selective toxicity to pancreatic β -cells via generation of NO free radicals. It is well known that the activity of free radical scavenging compounds i.e. antioxidant enzymes is very low in the islet of Langerhans of the pancreas as compared to the other tissues.³ Streptozotocin-induced diabetes in rats was associated with functional and/or morphological changes in the kidney and liver. It is possible that chromium picolinate would improve associated metabolic disturbances. Furthermore, chromium is a transition element, the toxic effects of chromium picolinate on these organs are investigated. The study of histopathological and functional alterations of control rats treated chronically with chromium picolinate may provide evidence of long term safety of the compound.⁴

Sonchus arvensis L. leaves is a plant-derived from Eurasia. It is known to have efficacy as a diuretic, anti-inflammation and anti-pyretic. *Sonchus arvensis* L. contains flavonoid in the form of luteolin, luteolin 7-O glucoside, kaempferol, orientin, and quercetin.⁵ Flavonoids are phenolic components that have antioxidant activity with a mechanism that is to fight free radicals in the body (*direct radical scavenging*), bind NO (Nitric Oxide), prevent xanthine oxidase, immobilize leukocytes and interact with other enzyme systems.⁶

Based on the potential and content of compounds contained in tempuyung leaves, the researchers are interested in knowing whether the administration of ethanol extracts obtained from *Sonchus arvensis* L leaves in dosage variations affects as well as knowing effective doses of glucose, creatinine and urea rats. streptozotocin-induced males.

Cite this article: Tandji J, Sutrisna NE, Pratiwi M, Handayani TW. Potential Test of Nephropathy *Sonchus arvensis* L. Leaves on Male Rats (*Rattus norvegicus*) Diabetes Mellitus. Pharmacogn J. 2020;12(5):1115-20.

MATERIAL AND METHODS

Tools and materials

Tools

The tools used in this study include: glassware (*pyrex*), sieve number 40 mesh, maceration vessels, blenders (*kirin*), test animals drinking bottles, porcelain cups, wood guttering, Glucometer (*Accu-check*), Glucotest strip test (*Accu-check*), incubator, test animal cage, cloth / lap, mortar and pestle, 25 mL and 100 mL measuring flask, rotary vacuum evaporator, injection syringe 1 ml, 3 ml, (*one mad*), oral syringes, markers, stopwatches, test tubes, analytical scales (*Ohaus*) where to eat test animals, gram scales (*cook masters*), and water baths, cassette embedding, surgical scissors (*Smics*), incubator, Olympus CX 21 (*Leica*) light microscope, microtome knife, scalpel (*Smics*), test tube, 3 mL vacuum tube (*EDTA vacutainer*).

Materials

The materials used in this study include *Sonchus arvensis* L. leaves from the Pasangkayu sub-district, West Sulawesi Province. Wistar strain male white rats obtained from test animal providers, distilled water, hydrochloric acid, aqua injection pro, iron (iii) chloride, citrate-buffer saline, dragendrof LP, 96% absolute ethanol, ether, glibenclamide (*indofarma*), handskun (*sensi*), cotton, label paper, filter paper, duct tape, mask, standard feed, magnesium powder, CMC Na 0.5%, and 40 mg Streptozotocin. ethanol 70%, ethanol 100%, ether, entellan (*Merck glue*), formalin 10% (*Merck*), dyes HE, paraffin, toluene, xylol.

Chemicals and streptozotocin-induced diabetes

Diabetes mellitus was induced by a single intraperitoneal (IP) injection of freshly prepared STZ at a dose of 40 mg/kg BW. dissolved in 0.01 M citrate buffer, pH 4.5 after 24 h of STZ injection, and overnight fast, blood was taken from the tail artery of the rats. an animal with an FBG level of higher than 250 mg/dl was selected for the diabetic groups.⁷

Making ethanol Extract of *Sonchus arvensis* L. Leaves

Sonchus arvensis L. leaf extract is done with maceration method, *Simplicia Sonchus arvensis* L. leaves which have been made into powder, extracted with using 96% ethanol solvent.

Research samples

This type of research is quasi-experimental with posttest group design. Using male Wistar rats, aged 8 weeks, BB 250-300 totaling 30 tails, mice induced by streptozotocin (STZ) single dose 40 mg/kg BW. The mouse is then divided into 5 groups. Group A: normal control, Group B: negative control (DM uncontrolled), Group C: positive control (DM rats with glibenclamide therapy 0.45 mg / kg BW), Group D: DM rats with 200mg / Kg BW therapeutic extract, Group E: DM rats with 300mg / Kg BW extract therapy, Group F: DM rats with 400mg / Kg BW extract therapy. Fasting blood glucose (GDP) was measured with a glucometer on days 7, 14 and 21.

Preparation of histopathological preparations for male white mouse kidney organs

After the kidney organ is removed from the body of the rat, the preparation of the kidney organ is made in the following steps: Hold organ laundering washed using 0.9% NaCl, section fixation with 10% formalin solution, section cutting of specimens using a knife cut, the stage of dehydration terraced using alcohol 70%, 80%, 90% and 95%, the clearing stage (purification) using toluene 3 times, each for 1-2 hours, the stage of paraffin infiltration using pure paraffin I, pure paraffin II and pure paraffin III, then embedding is done, stage organ inserted into the block of paraffin, sectioning stage, cutting blocks of

organs using a knife microtome. With the intensity of 4 micron slices, section attachment, using entellan (*brands*), section deparafinasi, using xylol for 15 minutes, section staining, dipped into alcohol 95%, 80%, 70%, 60%, 50%, 40%, 30%, distilled water 10 seconds, then staining hematoxylin. Washed running water, dipped back into alcohol 30%, 40%, 50%, 60%, 70% then eosin. Then back to 70% alcohol, 80%, 95% then xylol for 10 minutes, dripped with balsam Canada then covered with glass cover.

Data collection and analysis techniques

All data were analyzed using the SPSS 23 program with normality and homogeneity tests, then using the One Way Anova test for normal and homogeneous data and Kruskal Wallis for abnormal and non-homogeneous data at 95% confidence level.

RESULTS AND DISCUSSION

Sonchus arvensis L. leaf extract obtained from dried *Simplicia* 1,050 grams is as much as 71 grams with a yield of 6.76%. Qualitative analysis on a plant sample aims to determine whether or not there is a compound contained in a plant sample. Qualitative analysis of *Sonchus arvensis* L. leaf extract was carried out to ensure that this plant contained secondary metabolites including flavonoids, phenols, alkaloids, tannins, and saponins. The results of the qualitative analysis of *Sonchus arvensis* L. leaf extract showed results by the literature, namely *Sonchus arvensis* L. leaf extract containing flavonoid compounds, phenols, alkaloids, tannins, and saponins. The results of testing the analysis of extracts from *Sonchus arvensis* L.

Statistical testing of the results of the measurement of blood glucose levels of the test animal groups on days 0, 7, 14, 21 and 28 was performed by One Way ANOVA analysis (One Way Anova). Based on the results of one way ANOVA statistical test shows the use of ethanol extract of *Sonchus arvensis* L leaves at a dose of 200 mg/kg BW, 300 mg/kg body weight and 400 mg/kg body weight can affect reducing blood glucose levels. Based on the results obtained, a dose of 300 mg/kg BW is the most effective dose in reducing blood glucose levels comparable to positive control (glibenclamide) and approaching the normal group blood glucose levels. *Kruskal-Wallis* statistical results of histopathological scoring showed $p = 0.00$, i.e. ($p < 0.05$), for histopathological score, which showed that there were significant differences in the 3 treatment groups (200 mg/kg BW dose, 300 mg/kg BW dose, dose 400 mg/kg body weight) with normal and negative controls, so that further *Mann-Whitney* tests were performed to see significant differences between treatment groups.

Normal control group showing a good cuboidal epithelial structure in the proximal and distal tubules. The lumen of the tubule also appears wide and shows a brush border that is still intact and no protein cast is found in the lumen of the tubules or the pollen of inflammatory cells. In the negative control group which is a group of uncontrolled diabetic animal models there is an accumulation of inflammatory cells in the interstitial and begin to shrink from the basement membrane tubules and partially lose the brush border. Besides that, the tubules also experience atrophy and destruction compared to normal tubules and there are intraluminal casts, and estimated damage of about 25-50% in each field of view.

In the treatment group the dose of 200 mg/kg body weight was seen to be repaired from the injury, ie the brush border that was still attached to the epithelium and intact epithelial cells. There are still inflammatory cell pollutants but in small amounts. Tubular dilation in some areas was still found but in a smaller amount than the negative control group. This was similar to the treatment group with a dose of 300 mg/kg body weight which showed better tissue repair. In the treatment group the dose of 400 mg/kg body weight, histopathological changes were still

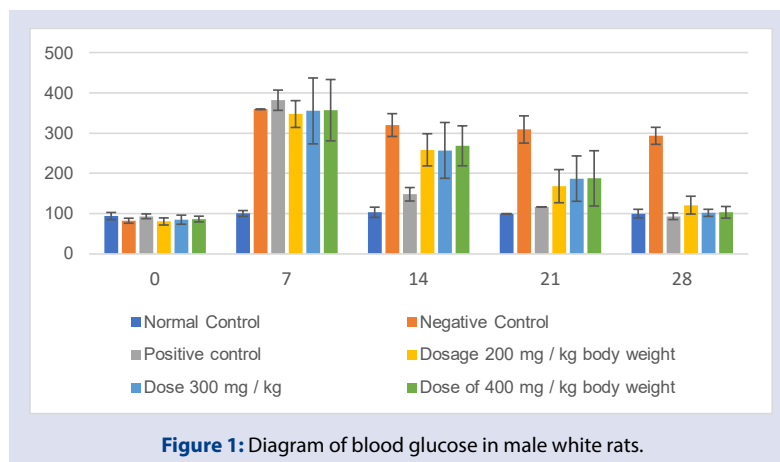


Figure 1: Diagram of blood glucose in male white rats.

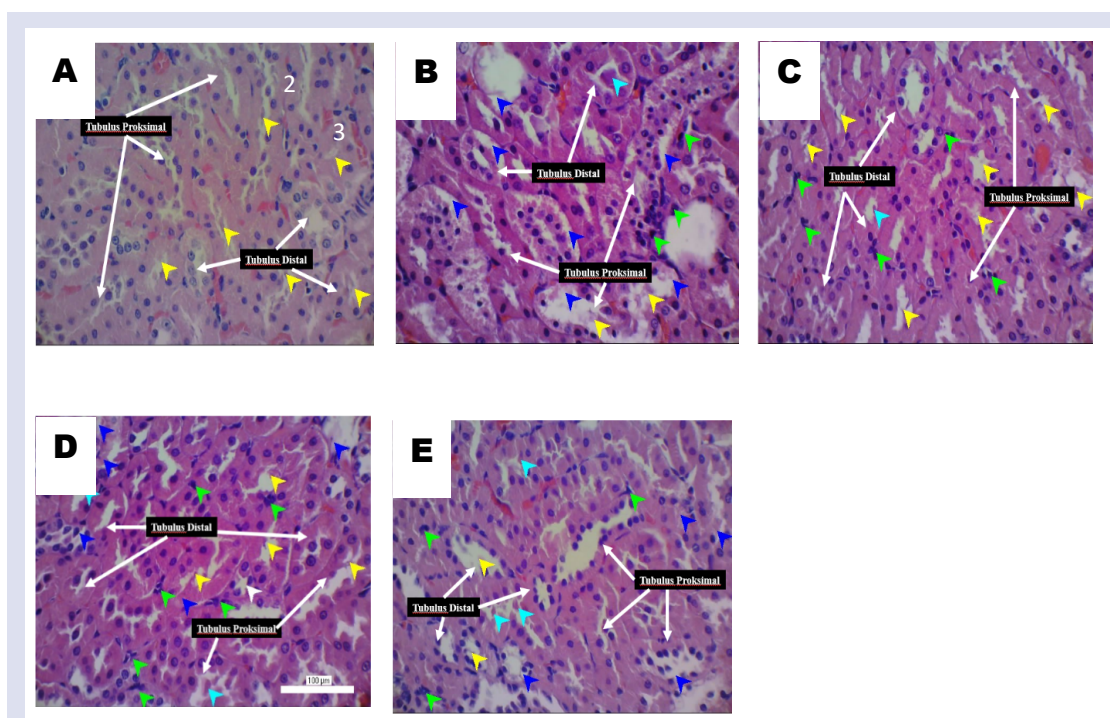


Figure 2: Kidney tubule injury with HE staining of Diabetes Mellitus model. Magnification 400 times and 100 μm scale. Description: A) Normal Group, (B) Negative Group, (C) Dose Group 200 mg / kg BW, (D) Group 300 mg / kg BW, (E) Group 400 mg / kg BW. Yellow arrows indicate brush borders, green arrows called inflammatory cells, blue arrows indicate shrinkage of the tubular membrane, light blue arrows indicate intraluminal cast, white arrows indicate tubular atrophy.

Table 1: Phytochemical Test Results of *Sonchus arvensis* L. (*Sonchus arvensis* L.) Leaf Extract.

NO	Chemical Content	Reactor	Observation result	Ket
1	Alkaloids	Dragendorf reagent	Orange color is formed	+
2	Flavonoids	Magnesium P + HCL	Yellow-orange color is formed	+
3	Saponin	Aquades	Foam formed for 15 minutes	+
4	Tannin	FeCl ₃ 1%	Black or black	+
5	Polyphenols	FeCl ₃ 5%	Black or black	+

Table 2: Average Blood Glucose Levels of Male White Rats Induced by Streptozotocin After Giving *Sonchus arvensis* L. Leaf Ethanol Extract.

Days to-	Average \pm SD Blood Glucose Level (mg / dL)						P.
	Normal Control	Negative Control	Positive control (Glibenclamide)	Dosage 2 00 mg / kg body weight	Dose 3 00 mg / kg	Dose of 40 0 mg / kg body weight	
0	93.6 \pm 8.96	82 \pm 6, 28	93 \pm 5.87	8 0.2 \pm 8.87	84.6 \pm 11.32	86.2 \pm 7.12	0.0 79
7	100 \pm 7.31	359 \pm 2 1, 55	381.8 \pm 25.23	347.4 \pm 33.35	355, 2 \pm 81,97	357 \pm 76.32	0.00 0
14	103 \pm 12, 74	320 \pm 28, 3 9	147.8 \pm 16, 78	258.4 \pm 40	257 \pm 69.43	268.4 \pm 49.73	0 000
21	99.4 \pm 1 3, 6 8	309 \pm 33.86	116.6 \pm 19, 26	168, 4 \pm 41.26	186.8 \pm 56.47	187.4 \pm 68.75	0.00 0
28	99.8 \pm 10, 63	293.2 \pm 21.18	93, 2 \pm 8, 3 1	120.8 \pm 22.17	101.6 \pm 8.82	103 \pm 14.43	0.00 0

Source: Primary Data 2019

Table 3: Scoring Level of Kidney Damage in Male White Rats (*Rattus Norvegicus*).

Treatment group	Damage Score				Average \pm SD damage
	1	2	3	4	
Normal Control	0	-	-	-	0.04 \pm 0.05
Negative Control (-)	0	2,4	-	-	1.3 \pm 0.87
<i>Sonchus arvensis</i> L. Leaf Extract Dose 200 mg / kg BW	0	-	-	-	0.5 \pm 0.18
<i>Sonchus arvensis</i> L. Leaf Extract Dose 300 mg / kg BW	0	-	-	-	0.28 \pm 0.18
<i>Sonchus arvensis</i> L. Leaf Extract Dose 400 mg / kg BW	0	1,1	-	-	0.44 \pm 0.37

Source: Primary data 2019

Note: 0 = normal, 1 = tubular injury <25% visual field, 2 = tubular injury involving 25% -50% visual field, 3 = tubular injury involving > 51% -75% visual field, 4 = tubular injury involving > 75 % field of view.

Table 4: Mann Whitney Test Results.

Treatment group	K. Normal	K. Negative	Dose of 200 mg / kg BW	300 mg / kg body BW	Dose of 400 mg / kg BW
K. Normal	-	0.008 *	0.008 *	0.008 *	0.008 *
K. Negative	0.008 *	-	0.073	0.008 *	0.046 *
Dose of 200 mg / kg body weight	0.008 *	0.073	-	0.041 *	.286
300 mg / kg body weight dose	0.008 *	0.008 *	0.041 *	-	.661
Dose of 400 mg / kg body weight	0.008 *	0.046 *	.286	.661	-

Note: p value <0.05 = * is significantly different and p value > 0.05 = insignificant different.

seen more than the treatment group the dose of 300 mg/kg body weight. In the treatment group the dose of 400 mg/kg body weight still shows tubular atrophy and widening of the interstitial space and intraluminal cast.

The results of the tubular injury score in 5 sample groups, it was found that the negative control group had the highest tubular injury score compared to the tubular injury score in the normal control group. Improvement of tubular injury scores began to appear in the treatment group dose of 200 mg/kg body weight, the dose of 300 mg/kg body weight and dose of 400 mg/kg body weight which received *Sonchus arvensis* L. leaf ethanol extract therapy was lower than the tubular injury score in the negative control group. This shows that this mouse model can cause changes in renal tubules that end with diabetic nephropathy. Chronic inflammatory conditions in diabetes mellitus will encourage the accumulation of inflammatory cells which in turn triggers kidney fibrosis. In this study, it was found that the administration of *Sonchus arvensis* L. leaf ethanol extract in diabetic animal models can inhibit tubular injury.

The effects of *Sonchus arvensis* L. leaves are caused by the presence of alkaloids, flavonoids, phenols, saponins, and tannins.⁸ The compounds that act as antioxidants are flavonoid compounds with its main component type quercetin⁹ the phases of quercetin to reduce MDA

levels by increasing the amount of natural antioxidant compounds. The use of *Sonchus arvensis* L. leaf extract with quercetin content can give an exception to the antioxidants from the outside with a slightly weak effect due to the condition of diabetes. Quercetin can reduce the formation of a Radikal free by balancing *reactive oxygen species* (ROS) and provide a protective role against cell membranes that can prevent lipid peroxidation.^{10,11} when antioxidants have bound to excessive ROS, cells damaged by ROS have regenerated time. These events can be seen that the ethanol extract of *Sonchus arvensis* L leaves can influence the regeneration of cells damaged in tubular cells due to free radicals.

CONCLUSION

Sonchus arvensis L. leaves ethanol extract has secondary metabolite compounds including alkaloids, flavonoids, phenols, tannins, and steroids. *Sonchus arvensis* L. leaves ethanol extract 300 mg/kg BW is an effective dose to reduce blood glucose levels which is comparable to positive control. *Sonchus arvensis* L. leaves ethanol extract effects the regeneration of kidney tubules cells with an effective dose of 300 mg/kg BW with an average damage value of 0.28.

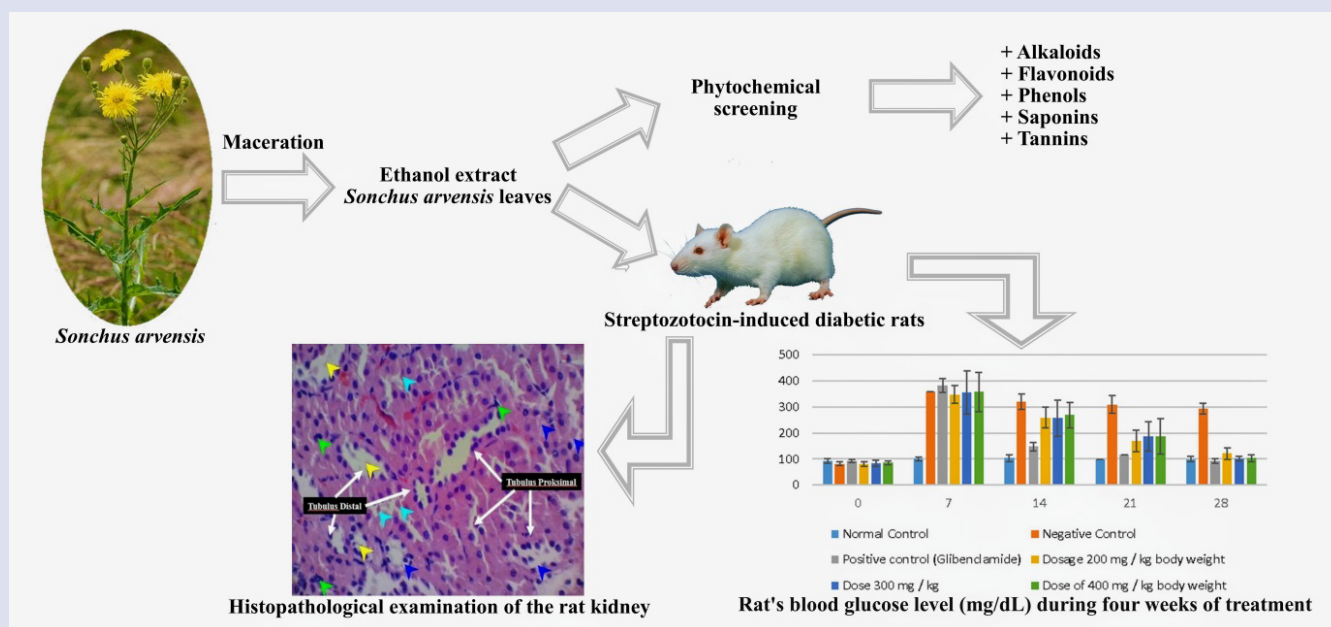
CONFLICTS OF INTEREST

The authors declare no conflicts of interest.

REFERENCES

1. Jelodar G, Maleki M, Sirius S. Effect of fumitory, celery, and lemon on blood glucose and histopathology of pancreas of alloxan diabetic rats. *Journal of Applied Animal Research*. 2007;31(1):101-4.
2. Tandil J, Claresta JA, Ayu G, Irwan I. Effect Of Ethanol Extract Of Kenikir (*Cosmos caudatus* Kunth.) Leaves in Blood Glucose, Cholesterol and Histopathology Pancreas of Male White Rats (*Rattus norvegicus*). *Pharmaceutical Science and Technology*. 2018;1(1):70-8.
3. Ahmed D, Kumar V, Verma A, Sharma M, Sharma M. Antidiabetic, antioxidant, antihyperlipidemic effect of extract of *Euryale Ferox* salisb. With enhanced histopathology of pancreas, liver and kidney in streptozotocin-induced diabetic rats. *SpringerPlus*. 2015;4(1).
4. Shinde UA, Goyal RK. Effect of chromium picolinate on histopathological alterations in STZ and neonatal STZ diabetic rats. *Journal of Cellular and Molecular Medicine*. 2003;7(3):322-9.
5. Khan RA. Evaluation of flavonoids and diverse antioxidant activities of *Sonchus arvensis*. *Chemistry Central Journal*. 2012;6(1):1-7.
6. Robert J Nijveldt, Els van Nood, Danny EC van Hoorn, Petra G Boelens, Klaske van Norren, PA van L. Flavonoids : a review of probable mechanisms of action. 2001;418-25.
7. Alimohammadi S. Protective and antidiabetic effects of extract from *Nigella sativa* on blood glucose concentrations against streptozotocin-induced diabetic in rats: an experimental study with histopathological evaluation. *Diagnostic Pathology*. 2013;8(37):1-7.
8. Abdullah A, Dhaliwal KK, Roslan NNF, Lee CH, Kalaiselvam M, Radman H M, et al. The effects of *Cosmos caudatus* (Ulam Raja) on detoxifying enzymes in extrahepatic organs in mice. *Journal of Applied Pharmaceutical Science*. 2015;5(1):082-8.
9. Tandil J, As S, Nazir R, Bukhari A. (n.d.). Test of Ethanol extract Red Gedi Leaves (*Abelmoschus Manihot* . (L.) Medik) in White Rat (*Rattus Norvegicus*) Type 2 Diabetes Mellitus. 4531:84-94.
10. EL-Baky AEA. Quercetin Protective Action on Oxidative Stress, Sorbitol, Insulin Resistance and B-Cell Function in Experimental Diabetic Rats. *Int J Pham Stud Res*. 2011;11(2):11-8.
11. Tandil J, Danthi R, Purwaningsih, Kuncoro H. Effect of Ethanol Extract from Purple Eggplant Skin (*Solanum melongena* L) On Blood Glucose Levels and Pancreatic B Cells Regeneration on White Rats Male Hypercholesterolemia-Diabetic. *Research Journal of Pharmacy and Technology*. 2019;12(6):2936-42.

GRAPHICAL ABSTRACT




ABOUT AUTHORS




Joni Tandil is a researcher (lecturer) in College of Pharmaceutical Sciences Pelita Mas Palu, Central Sulawesi, Indonesia.



I Nyoman Edi Sutrisna is a researcher in College of Pharmaceutical Sciences Pelita Mas Palu, Central Sulawesi, Indonesia.



Mentari Pratiwi is a researcher in College of Pharmaceutical Sciences Pelita Mas Palu, Central Sulawesi, Indonesia.



Tien Wahyu Handayani is a researcher (lecturer) in College of Pharmaceutical Sciences Pelita Mas Palu, Central Sulawesi, Indonesia.

Cite this article: Tandi J, Sutrisna NE, Pratiwi M, Handayani TW. Potential Test of Nephropathy *Sonchus arvensis L.* Leaves on Male Rats (*Rattus norvegicus*) Diabetes Mellitus. *Pharmacogn J.* 2020;12(5):1115-20.