

# The Role of $\alpha$ -SMA, Type 1 Collagen, and Myofibroblasts in Cicatrizing Conjunctivitis by Alkali Chemical Trauma

Henu Hadiyantama<sup>1</sup>, Lukisiari Agustini<sup>1\*</sup>, Sutjipto<sup>1</sup>, Evelyn Komaratih<sup>1</sup>, Ismi Zuhria<sup>1</sup>, Pudji Lestari<sup>2</sup>, Ridholia<sup>3</sup>

Henu Hadiyantama<sup>1</sup>, Lukisiari Agustini<sup>1\*</sup>, Sutjipto<sup>1</sup>, Evelyn Komaratih<sup>1</sup>, Ismi Zuhria<sup>1</sup>, Pudji Lestari<sup>2</sup>, Ridholia<sup>3</sup>

<sup>1</sup>Department of Ophthalmology, Faculty of Medicine, Universitas Airlangga/Dr. Soetomo General Academic Hospital, Surabaya, INDONESIA.

<sup>2</sup>Department of Public Health, Faculty of Medicine, Universitas Airlangga, Surabaya, INDONESIA.

<sup>3</sup>Department of Pathology Anatomy, Faculty of Medicine/Dr. Soetomo General Academic Hospital, Universitas Airlangga, Surabaya, INDONESIA.

## Correspondence

Lukisiari Agustini

Department of Ophthalmology, Faculty of Medicine, Universitas Airlangga/Dr. Soetomo General Academic Hospital, Surabaya, INDONESIA.

E-mail: lukisiari.agustini@fk.unair.ac.id

## History

- Submission Date: 10-03-2024;
- Review completed: 18-04-2024;
- Accepted Date: 24-04-2024.

DOI : 10.5530/pj.2024.16.

Article Available online

<http://www.phcogj.com/v16/i3>

## Copyright

© 2024 Phcogj.Com. This is an open-access article distributed under the terms of the Creative Commons Attribution 4.0 International license.



## ABSTRACT

**Introduction:** Chemical trauma to the eye is a serious condition in the field of ophthalmology and a leading factor contributing to global blindness. Cicatrizing conjunctivitis (CC) is a term used to describe conditions marked by inflammation and the formation of scars on the conjunctiva. CC can have various causes, with one of them being chemical injury to the eye. The development of CC involves the participation of several cytokines and cells, such as  $\alpha$ -SMA, Type 1 collagen, and Myofibroblasts. Myofibroblasts have the ability to contract through the utilization of diverse cytoskeletal proteins, which are commonly present in smooth muscle cells, including  $\alpha$ -SMA. Actin filaments contribute to mechanically supporting cells, defining cell morphology, and facilitating cell mobility. Actin, in conjunction with myosin, participates in the muscle contraction process within muscle cells. Subsequently, type 1 collagen contributes to the healing of conjunctival wounds by providing a tensile force that aids in the closure of such wounds. As a significant constituent of the extracellular matrix, type 1 collagen plays a crucial role in maintaining the integrity of tissues.

**Keywords:** Cicatrizing conjunctivitis,  $\alpha$ -SMA, Type 1 collagen, and Myofibroblasts.

## INTRODUCTION

Chemical trauma to the eyes is a critical condition in ophthalmology and a major cause of blindness worldwide. Chemical trauma caused by alkaline solutions can result in more severe damage because it induces saponification reactions of fatty acids in cell membranes, thereby damaging corneal and conjunctival epithelial tissues. This trauma triggers the wound-healing process in the conjunctiva. Sodium hydroxide, calcium hydroxide, and ammonium hydroxide are the most common chemicals causing eye chemical trauma. Although several studies have investigated cicatrizing conjunctivitis, the molecular mechanisms underlying its occurrence remain uncertain. Therefore, there is currently no precise method for preventing and addressing cicatrizing conjunctivitis resulting from alkali chemical trauma.<sup>1-7</sup>

Previous research reports an incidence rate of eye chemical trauma ranging from 10.7% to 34.7% of total chemical trauma cases. Alkali chemical trauma occurs more frequently than acid chemical trauma, as these substances are commonly used in households and industries. The incidence rate of alkali chemical trauma to the eyes reaches 66.7% - 67.9%, while acid chemical trauma ranges from 5% - 47.6%. Ahmmed et al. reported an incidence of eye chemical trauma ranging from 5.1 - 50 per 100,000 population per year. The most at-risk group comprises young adult males and children.<sup>1,8,9</sup> Accurate epidemiological information on cicatrizing conjunctivitis (CC) is limited, with reliable data primarily obtained from two extensive prospective studies conducted in the United Kingdom, indicating an incidence of 1.3 cases per million, and in Australia/New Zealand, indicating an incidence of 1.5 cases per million.<sup>10,11</sup> The management of cicatrizing

conjunctivitis (CC) depends on its underlying cause. If CC is not treated properly, it can lead to several complications. One of the complications of CC is the occurrence of symblepharon.<sup>12</sup> The approach to symblepharon management involves both medical and surgical methods. According to Cheng et al., cultivated limbal epithelial transplantation (CLET) therapy for symblepharon resulting from eye chemical trauma had a success rate of only 50%, with 18.8% experiencing recurrent symblepharon.<sup>13</sup> Shan et al. conducted a study on decellularized porcine conjunctiva (DPC) in patients with symblepharon, revealing a success rate of only 75%, with 6.25% experiencing failure.<sup>14</sup> These findings highlight a relatively low success rate in managing complications of CC.

The purpose of this literature review is to discuss the roles of  $\alpha$ -SMA, type 1 collagen, and myofibroblasts in CC resulting from chemical trauma. The high incidence of chemical trauma that has the potential to cause CC, the relatively high failure rate of CC therapy, and the lack of information on molecular mechanisms have all contributed to the interest in conducting this literature review.

## Ocular Chemical Trauma

Chemical trauma to the eyes can result in extensive damage to the ocular epithelial tissues, including the cornea and anterior segment up to the limbal stem cells, leading to potential permanent vision impairment. Based on the causative agents, ocular chemical trauma is categorized into acid chemical trauma and alkali chemical trauma. Alkali substances are more commonly found in industrial products and cleaners, making alkali chemical trauma more prevalent than acid chemical trauma. Ocular chemical trauma is considered an emergency condition that requires immediate attention. Several

**Cite this article:** Hadiyantama H, Agustini L, Sutjipto, Komaratih E, Zuhria I, Lestari P, Ridholia. The Role of  $\alpha$ -SMA, Type 1 Collagen, and Myofibroblasts in Cicatrizing Conjunctivitis by Alkali Chemical Trauma. *Pharmacogn J.* 2024;16(3):.

classifications categorize chemical trauma based on the degree of damage and prognosis, taking into account the extent of tissue damage to the conjunctiva, limbus, and cornea.<sup>6,7,15-17</sup>

Alkaline chemicals are lipophilic and can penetrate the eyes more rapidly than acids. Alkali substances with hydroxyl ions can quickly precipitate on the surface tissues of the eye, triggering saponification reactions on the fatty acid cell membrane, leading to cell disruption. Damaged tissues will release proteolytic enzymes as an inflammatory response, causing further damage.<sup>6,7,16-19</sup>

## Cicatrizing Conjunctivitis

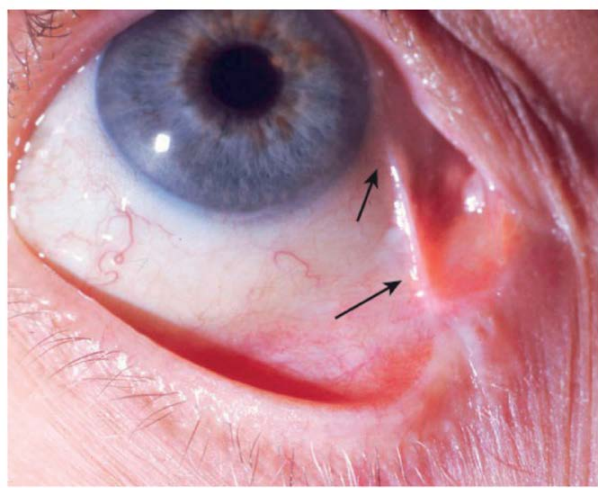
Cicatrizing conjunctivitis (CC) encompasses situations where there is inflammation and the formation of scars in the conjunctiva. The range of clinical manifestations associated with cicatrization extends from subtle subconjunctival fibrosis to significant distortion of the ocular surface anatomy, including conditions like ankyloblepharon.<sup>11,12</sup>

CC can be caused by both exogenous and endogenous factors. Exogenous causes include ocular surface chemical or thermal burns and pterygium. Endogenous causes include Steven-Johnson syndrome (SJS), toxic epidermal necrolysis (TEN), atopic keratoconjunctivitis (AKC), vernal keratoconjunctivitis (VKC), ocular cicatricial pemphigoid (OCP) and mucous membrane pemphigoid (MMP). CC can also result from side effects of drug reactions or may occur after glaucoma filtering surgery (GFS) as a consequence of changes in the conjunctival epithelial surface.<sup>5,10,12,20-24</sup>

Clinical manifestations of CC vary based on the frequency, intensity, and underlying cause of conjunctival inflammation. Early and subtle indicators may encompass caruncular or subconjunctival fibrosis, which could advance to fornical foreshortening and the formation of symblepharon (Figure 1). In more progressed instances, patients may exhibit a dry ocular surface, plica semilunaris loss, keratin deposits on the ocular surface or lid margin, disruption of the normal architecture of the lid margin and mucocutaneous junction, entropion, trichiasis, distichiasis, ankyloblepharon, and dermalization of the ocular surface. Long-standing cases of CC often feature limbal stem cell deficiency (LSCD).<sup>11,12</sup>

## Pathophysiology of Cicatrizing Conjunctivitis

The pathophysiology of CC varies depending on the etiology. One of the etiology of CC is chemical trauma. Chemical trauma can damage the anatomical structure of the conjunctiva which then stimulates the



**Figure 1.** Symblepharon connecting the lid margin and perilimbal conjunctiva is observed in ocular cicatricial pemphigoid.<sup>25</sup>

conjunctival healing process. Wound healing is a complex and dynamic series of phases involving various types of cells, cytokines, mediators, and the vascular system. The wound healing process is divided into four phases: hemostasis phase, inflammation phase, proliferation phase and remodeling phase (Figure 2).<sup>26-28</sup>

Hemostasis phase is the first stage of the wound healing process. The primary goal of this phase is to stop bleeding. Chemical trauma lead to release of blood products. Platelet activation plays a crucial role in the wound healing process by releasing cytokines and growth factors that contribute to the coagulation cascade. Growth factors release include platelet-derived growth factor (PDGF), vascular endothelial growth factor (VEGF), transforming growth factor  $\beta$  (TGF- $\beta$ ) and potent cytokines namely interleukin, serotonin, thromboxane, thrombin, and platelet activating factor (PAF). These growth factors recruit neutrophils and monocytes to initiate the next stage of wound healing by stimulating epithelial cells.<sup>26-31</sup>

The inflammation phase is the second stage of the wound healing process, with the primary goal of preventing infection and cleaning the wound from bacteria that occurs within one hour after the wound and continues for 48-72 hours after the injury (Figure 2). Neutrophils, monocytes, and macrophages are key cells during the inflammatory phase.<sup>26-28,31</sup>

During this phase, neutrophils are the first inflammatory cells to respond to soluble mediators released by platelets and the coagulation cascade. Neutrophils carry out phagocytosis and granulation of toxic substances to destroy debris and bacteria. Neutrophils also secrete cytokines such as Fibroblast growth factor (FGF), TGF- $\beta$  and release pro-inflammatory mediators such as TNF- $\alpha$ , IL-1, and IL-6, which subsequently recruit and activate fibroblasts and epithelial cells. Macrophages play a role in continuing the cleaning process of debris.<sup>26,27,31</sup>

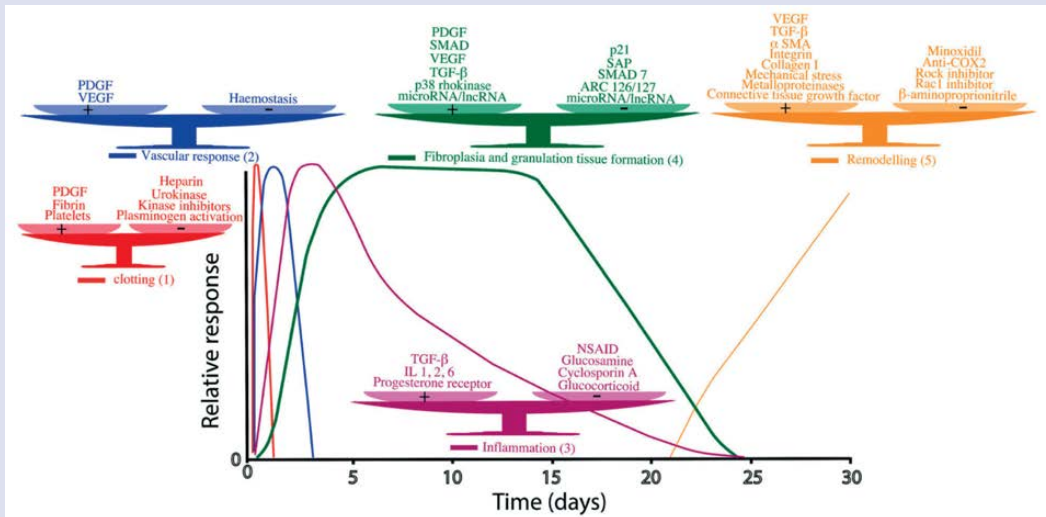
The proliferation phase focuses on tissue density replenishment and wound closure. There are two main factors in the proliferation phase namely angiogenesis and fibrogenesis. Angiogenesis is the process of forming new capillaries within the wound. Blood vessel growth begins 3-5 days after the injury. Angiogenesis is modulated by Fibroblast Growth Factor (FGF) and Vascular Endothelial Growth Factor (VEGF).<sup>26,27,30,31</sup>

Fibroblasts are essential for fibrogenesis, extracellular matrix production, and tissue remodeling. Fibroblasts migrate into the wound in response to soluble mediators released by platelets and macrophages on the 4th day, peaking on the 7th day, and continuing until the 14th day after the injury. Fibroblasts are activated and express  $\alpha$ -SMA, subsequently transforming into myofibroblasts. This activation is modulated by profibrogenic cytokines, namely PDGF and TGF- $\beta$ . Myofibroblasts synthesize and deposit extracellular matrix (ECM) to replace the provisional matrix. They express  $\alpha$ -SMA on microfilaments or stress fibers, contributing to the contraction and maturation of granulation tissue. Myofibroblasts attach to fibronectin and collagen in the extracellular matrix, playing a crucial role in wound closure.<sup>26,27,29-31</sup>

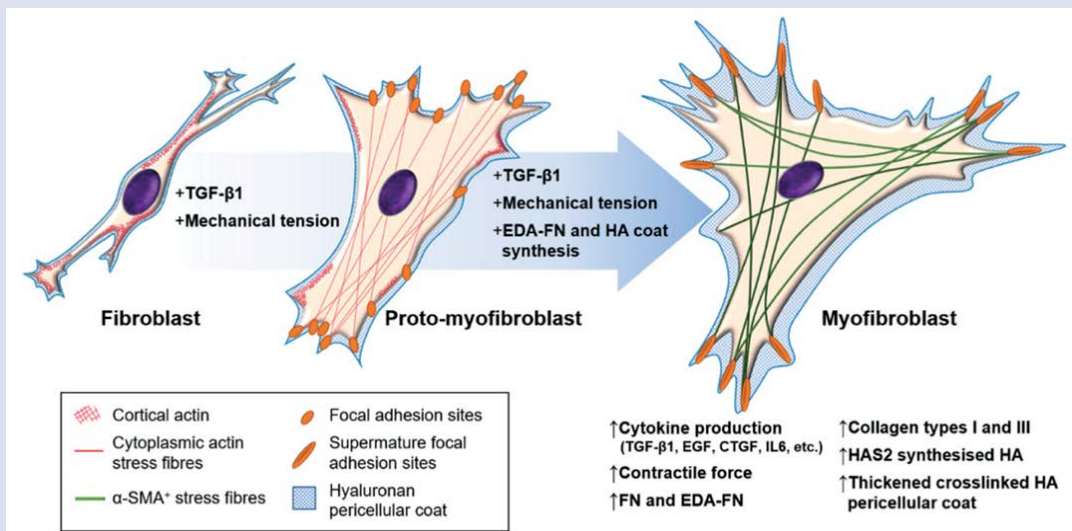
The final phase is the remodeling phase, and the goal of this phase is to refine the newly formed tissue into a strong healing tissue by rearranging the structure and collagen tissue to produce strength and elasticity. The remodeling phase involves the maturation of fibrovascular tissue into mature scar tissue. This phase runs from day 21 to 2 years after the injury.<sup>26,27</sup>

## Myofibroblast and $\alpha$ -SMA Role

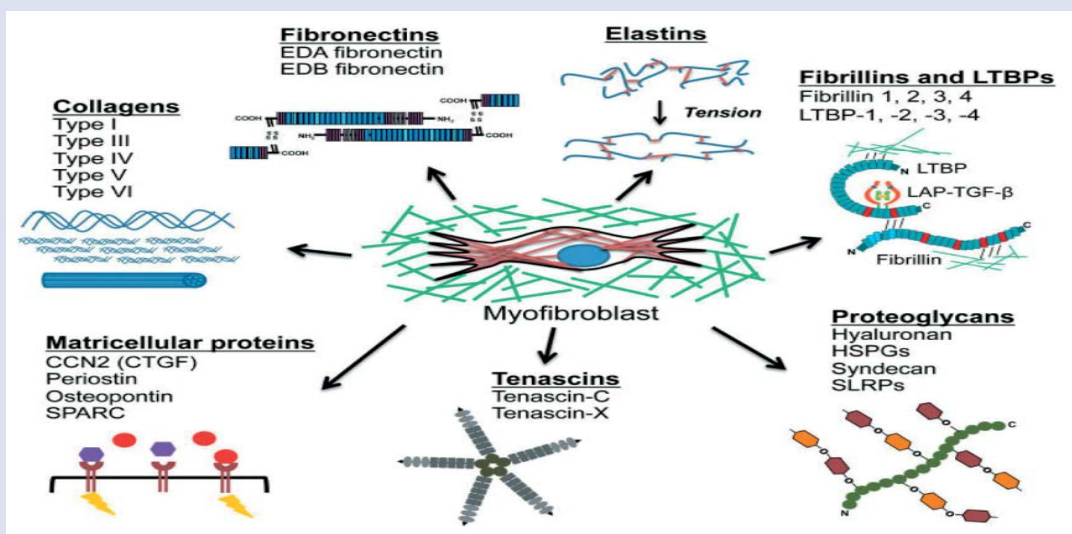
Myofibroblasts are involved in several fibrotic and scarring diseases, where they play a crucial role in the aftermath of the initial injury by providing mechanical support and integrity to the tissue. In



**Figure 2.** The conjunctival healing process consists of hemostasis, inflammation, granulation tissue formation (proliferation), and remodeling phases. Conjunctival healing involves various growth factors, cytokines, receptors, enzymes, and different types of cells.<sup>2</sup>



**Figure 3.** Fibroblast-myofibroblast differentiation.<sup>35</sup>



**Figure 4.** The myofibroblast matrix.<sup>37</sup>



pathological conditions, myofibroblasts often fail to undergo apoptosis, persist within the wound, and contribute to the formation of persistent scar tissue.<sup>30,32,33</sup>

Fibroblast transformation into myofibroblast occurs in two steps: first, the formation of protomyofibroblast, followed by the development into myofibroblast. The transformation of protomyofibroblasts into myofibroblasts is modulated by the accumulation of transforming growth factor-beta (TGF- $\beta$ ), the presence of specialized extracellular cellular matrix (ECM) proteins such as the extra domain A (ED-A) splice variant of fibronectin, high extracellular stress arising from the mechanical properties of the ECM and cell remodeling activity, mast cells derive-histamine, tryptase and tumor necrosis factor- alpha (TNF  $\alpha$ ) (Figure 3).<sup>31-35</sup>

Myofibroblasts cease proliferation and begin synthesizing extracellular matrix proteins in large quantities when activated. While collagen I and collagen III are commonly mentioned as the main extracellular matrix (ECM) proteins generated by myofibroblasts, these cells also produce a diverse array of other ECM proteins in the process of wound healing and fibrosis. These include collagen types IV, V, and VI, glycoproteins, and proteoglycans like fibronectin, laminin, and tenascin (Figure 4).<sup>30,33,34,37,38</sup>

The key characteristic of the myofibroblast is the expression of  $\alpha$ -smooth muscle actin ( $\alpha$ -SMA) within stress fibers, serving as the molecular foundation for their heightened contractile capability. The force generated by myofibroblasts is transmitted to the ECM through focal adhesions containing specific transmembrane integrins. These cells have the ability to expedite tissue repair by causing edge-to-edge contraction of wounds. After the wound healing process is complete, myofibroblast cells undergo apoptosis. In some fibrotic conditions, the mechanism of myofibroblast apoptosis is believed to fail, leading to the persistence of myofibroblasts, excessive extracellular matrix expansion, and wound contracture. The substantial contractile force produced by myofibroblasts plays a vital role in tissue remodeling physiologically, but it has negative implications for tissue function when produced excessively, such as in hypertrophic scar cases.<sup>28,32-38</sup>

Actin is a globular structural protein that polymerizes in a helical pattern to form actin filaments. Actin filaments make up the cytoskeleton, a three-dimensional network within eukaryotic cells. Actin filaments play a role in mechanically supporting cells, determining cell shape, and enabling cell movement. Along with myosin, actin is involved in the process of muscle contraction within muscle cells. In the cytoplasm, most actin is bound to ATP, but actin can also bind to ADP.<sup>36</sup>

$\alpha$ -SMA has a molecular weight of 40 kD. Each subunit of actin is known as globular actin, while the filamentous polymer composed of G-actin subunits (microfilament) is known as F-actin. Microfilaments are the thinnest components of the cytoskeleton, with a diameter of 7 nm. Like microtubules, actin filaments are polar, with one end being positive and fast-growing and the other end being negative and slow-growing. ADP-actin dissociates from the negative end, and an increase in ADP-actin stimulates the exchange of ADP-actin with ATP-actin. This rapid turnover is crucial for cell movement.<sup>36</sup>

### Type 1 Collagen Role

Collagens are mainly structural proteins characterized by the arrangement of three procollagen chains in a classic triple helical pattern. Myofibroblasts synthesize several extracellular matrix proteins such as type 1 collagen during conjunctival wound healing. Type 1 collagen is the most abundant protein in the corneal and conjunctival stroma. This type 1 collagen subsequently aids in the conjunctival wound healing and provides a tensile force that assists in the closure of conjunctival wounds.<sup>37-39</sup>

Type 1 collagen is a major component of the extracellular matrix responsible for maintaining tissue integrity. Several studies indicate an increased ratio of type 1 collagen in keloid tissue, indicating the crucial role of type 1 collagen in the wound healing process. The production of type 1 collagen is triggered by an increase in TGF- $\beta$  levels. Research shows that the administration of substances that suppress TGF- $\beta$  levels results in a decrease in the production of type 1 collagen.<sup>38,40</sup>

## CONCLUSION

The process of cicatrizing conjunctivitis due to chemical trauma involves the conjunctival wound healing process in which myofibroblasts,  $\alpha$ -SMA, and type 1 collagen are also involved. Myofibroblasts, characterized by the expression of  $\alpha$ -SMA, emerge as pivotal contributors to tissue repair, employing their enhanced contractile capability to facilitate wound closure.  $\alpha$ -SMA emphasizes its structural importance within the cytoskeleton and its active role in cell movement. Type 1 collagen, synthesized by myofibroblasts, emerges as a key player in maintaining tissue integrity.

## ACKNOWLEDGMENT

We would like to thank Dr. Lukisiari Agustini, dr. Sp.M(K), Stjtjpto, dr., Sp.M(K), Dr. Evelyn Komaratih, dr., Sp.M(K), Dr. Ismi Zuhria, dr., Sp.M(K), Dr. Pudji Lestari, dr., M.Kes and Ridholia, dr., Sp.M(K) for discussion and suggestion regarding the role of  $\alpha$ -SMA, type 1 collagen, and myofibroblast in symblepharon. We acknowledge that this literature review would not have been possible without the cooperation and contributions of all parties involved.

## FUNDING

There was no specific funding from governmental, commercial, or non profit entities for this paper.

## DISCLOSURE

The author has stated the absence of any conflict of interest regarding this paper.

## AUTHORS CONTRIBUTION

All authors contributed to article preparation and paper revision and have collectively assumed responsibility for all aspects of this paper.

## ETHICAL CONSIDERATION

No ethical consideration is needed for this paper because there is no intervention in humans or animals in this paper.

## DATA AVAILABILITY

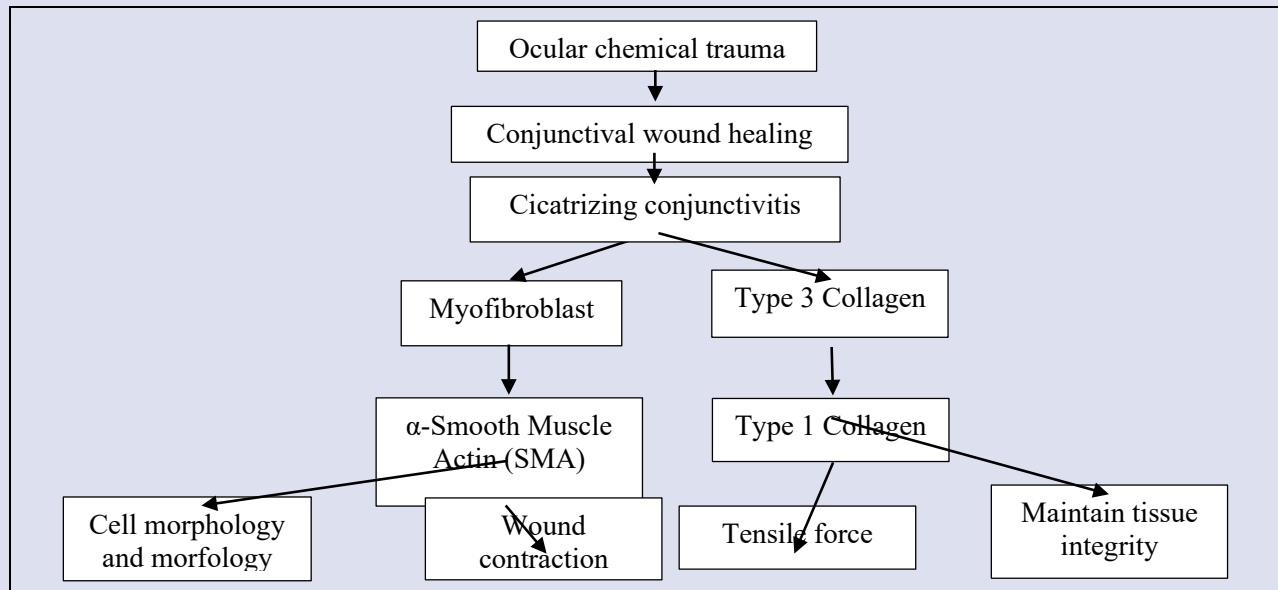
The article contains all the necessary data to support this paper; no supplementary source data is needed.

## REFERENCES

1. Akgun Z, Selver OB. Epidemiology and etiology of chemical ocular injury: A brief review. *World J Clin Cases*; 11. Epub ahead of print 26 February 2023. DOI: 10.12998/wjcc.v11.i6.1245.
2. Khaw PT, Bouremel Y, Brocchini S, et al. The control of conjunctival fibrosis as a paradigm for the prevention of ocular fibrosis-related blindness. "Fibrosis has many friends". *Eye*; 34. Epub ahead of print December 2020. DOI: 10.1038/s41433-020-1031-9.
3. Korn BS, Burkat CN, Carter KD, et al. Periocular Malpositions and Involuntional Changes. In: *Oculofacial Plastic and Orbital Surgery*. China: American Academy of Ophthalmology, 2022, pp. 229-266.
4. Rafailov L, R. Lazzaro D (eds). Corneal Trauma. In: *Textbook of Ocular Trauma: Evaluation and Treatment*. Cham: Springer International Publishing, pp. 5-16.

5. Swarup A, Ta CN, Wu AY. Molecular mechanisms and treatments for ocular symblephara. *Survey of Ophthalmology*; 67. Epub ahead of print 2021. DOI: 10.1016/j.survophthal.2021.04.008.
6. Fariz M, Indriaswati L. Effect of medroxyprogesterone and doxycycline on vascular endothelial growth factor (VEGF) expression and corneal neovascularization in corneal alkali trauma. *Bali Medical Journal*. 2023;12(2):1377-80. <https://www.balimedicaljournal.org/index.php/bmj/article/view/4366>
7. Juwita A, Agustini L, Loebis R, et al. Efficacy and safety of topical doxycycline reduce MMP-9 expression towards populations with corneal alkali burn. *Bali Medical Journal*. 2023;12(2), 1840–1845. <https://doi.org/10.15562/bmj.v12i2.4533>
8. Ahmmed AA, Ting DSJ, Figueiredo FC. Epidemiology, economic and humanistic burdens of Ocular Surface Chemical Injury: A narrative review. *The Ocular Surface*; 20. Epub ahead of print April 2021. DOI: 10.1016/j.jtos.2021.02.006.
9. Quesada JM-A, Lloves JM, Delgado DV. Ocular chemical burns in the workplace: Epidemiological characteristics. *Burns* 2020; 46: 1212–1218.
10. Radford CF, Rauz S, Williams GP, et al. Incidence, presenting features, and diagnosis of cicatrizing conjunctivitis in the United Kingdom. *Eye*; 26. Epub ahead of print September 2012. DOI: 10.1038/eye.2012.119.
11. Bobba S, Devlin C, Di Girolamo N, et al. Incidence, clinical features and diagnosis of cicatrizing conjunctivitis in Australia and New Zealand. *Eye* 2018; 32: 1636–1643.
12. Vazirani J, Donthineni P, Goel S, et al. Chronic cicatrizing conjunctivitis: A review of the differential diagnosis and an algorithmic approach to management. *Indian J Ophthalmol* 2020; 68: 2349.
13. Cheng J, Zhai H, Wang J, et al. Long-term outcome of allogeneic cultivated limbal epithelial transplantation for symblepharon caused by severe ocular burns. *BMC Ophthalmol*; 17. Epub ahead of print December 2017. DOI: 10.1186/s12886-017-0403-9.
14. Shan F, Feng X, Li J, et al. Decellularized Porcine Conjunctiva in Treating Severe Symblepharon. *JFB*; 14. Epub ahead of print 8 June 2023. DOI: 10.3390/jfb14060318.
15. Heath Jeffery RC, Dobes J, Chen FK. Eye injuries: Understanding ocular trauma. *Aust J Gen Pract* 2022; 51: 476–482.
16. Singh P, Tyagi M, Kumar Y, et al. Ocular chemical injuries and their management. *Oman J Ophthalmol*; 6. Epub ahead of print 2013. DOI: 10.4103/0974-620X.116624.
17. Weisenthal RW, Daly MK, de Freitas D, et al. Clinical Aspects of Toxic and Traumatic Injuries of the Anterior Segment. In: *Basic and Clinical Science Course : External Disease and Cornea*. san francisco: American Academy of Ophthalmology, 2021, pp. 375–381.
18. Mashige K. Chemical and thermal ocular burns: a review of causes, clinical features and management protocol. *South African Family Practice*; 58. Epub ahead of print 17 February 2016. DOI: 10.1080/20786190.2015.1085221.
19. Mishra BP, Sahu DSK, Mahapatra A, et al. Incidence and Management of Chemical Injuries of Eye. *jmscr*; 7. Epub ahead of print 25 June 2019. DOI: 10.18535/jmscr/v7i6.134.
20. Branisteanu D, Stoleriu G, Branisteanu D, et al. Ocular cicatricial pemphigoid (Review). *Exp Ther Med*. Epub ahead of print 7 July 2020. DOI: 10.3892/etm.2020.8972.
21. Chen L-B. Evaluation of chronic ocular sequelae in patients with symblepharon caused by ocular burns. *Int J Ophthalmol* 2020; 13: 1066–1073.
22. Penne RB (ed). Eyelid Malpositions. In: *Oculoplastics*. Philadelphia: Wolters Kluwer, 2019, pp. 106–185.
23. Stan C, Diaconu E, Hopirca L, et al. Ocular cicatricial pemphigoid. *rjo* 2020; 64: 226–230.
24. Taurone S, Spoletini M, Ralli M, et al. Ocular mucous membrane pemphigoid: a review. *Immunol Res* 2019; 67: 280–289.
25. Morrison J, Ma K. The Conjunctiva and the Limbus. In: *Anatomy of the Eye and Orbit: The Clinical Essentials*. China: Wolters Kluwer, 2018, pp. 221–249.
26. Kumar V, Abbas AK, Aster JC, et al. Inflammation and Repair. In: *Robbins basic pathology*. Philadelphia, Pennsylvania: Elsevier, 2018, pp. 57–93.
27. Mohan H. Inflammation and Healing. In: *Textbook of pathology*. New Delhi: Jaypee Brothers Medical Publishers, 2013, pp. 130–171.
28. Wiratama AB, Prastyani R, Wahyuni I, et al. The  $\alpha$ -smooth muscle actin ( $\alpha$ -SMA) and collagen type III expression of Platelet Rich Fibrin (PRF) membrane in conjunctival wound healing: a literature review. *Bali Medical Journal*. 12(3), 2538–2547. <https://doi.org/10.15562/bmj.v12i3.4746>.
29. Cordeiro MF, Chang L, Lim KS, et al. Modulating conjunctival wound healing. *Eye*; 14. Epub ahead of print May 2000. DOI: 10.1038/eye.2000.141.
30. Desmouliere A, Darby IA, Laverdet B, et al. Fibroblasts and myofibroblasts in wound healing. *CCID* 2014; 301.
31. Zada M, Pattamatta U, White A. Modulation of Fibroblasts in Conjunctival Wound Healing. *Ophthalmology*; 125. Epub ahead of print February 2018. DOI: 10.1016/j.ophtha.2017.08.028.
32. Hinz B. The role of myofibroblasts in wound healing. *Current Research in Translational Medicine* 2016; 64: 171–177.
33. Schuster R, Younesi F, Ezzo M, et al. The Role of Myofibroblasts in Physiological and Pathological Tissue Repair. *Cold Spring Harb Perspect Biol* 2023; 15: a041231.
34. Bagalad B, Mohan Kumar K, Puneeth H. Myofibroblasts: Master of disguise. *J Oral Maxillofac Pathol* 2017; 21: 462.
35. Bochaton-Piallat M-L, Gabbiani G, Hinz B. The myofibroblast in wound healing and fibrosis: answered and unanswered questions. *F1000Res*; 5. Epub ahead of print 26 April 2016. DOI: 10.12688/f1000research.8190.1.
36. Tai Y, Woods EL, Dally J, et al. Myofibroblasts: Function, Formation, and Scope of Molecular Therapies for Skin Fibrosis. *Biomolecules* 2021; 11: 1095.
37. Cherg S, Young J, Ma H. Alpha-smooth muscle actin ( $\alpha$ -SMA). *The Journal of American Science*; 4.
38. Klingberg F, Hinz B, White ES. The myofibroblast matrix: implications for tissue repair and fibrosis. *The Journal of Pathology* 2013; 229: 298–309.
39. Naomi R, Ridzuan PM, Bahari H. Current Insights into Collagen Type I. *Polymers* 2021; 13: 2642.
40. Witt J, Borrelli M, Mertsch S, et al. Evaluation of Plastic-Compressed Collagen for Conjunctival Repair in a Rabbit Model. *Tissue Engineering Part A* 2019; 25: 1084–1095.
41. Yonemura H, Futakuchi A, Inoue-Mochita M, et al. DNA methyltransferase inhibitor suppresses fibrogenetic changes in human conjunctival fibroblasts. *Molecular Vision*; 25

### GRAPHICAL ABSTRACT



**Cite this article:** Hadiyantama H, Agustini L, Sutjipto, Komaratih E, Zuhria I, Lestari P, Ridholia. The Role of  $\alpha$ -SMA, Type 1 Collagen, and Myofibroblasts in Cicatrizing Conjunctivitis by Alkali Chemical Trauma. *Pharmacogn J.* 2024;16(3):.