

# Identification of Murder Victims' Cranial Bone Mutilation Using Forensic Medicine, Anthropology, and Genotype DNA Approaches

Setya Aji Priyatna<sup>1\*</sup>, Satria Perwira<sup>2,4</sup>, Vernando Parlindungan Simanjuntak<sup>5</sup>, Sari Nur Indahty Purnamaningsih<sup>1</sup>, I Ketut Heru Suryanegara<sup>1</sup>, Desy Martha Panjaitan<sup>3</sup>, Ahmad Yudianto<sup>1</sup>

**Setya Aji Priyatna<sup>1\*</sup>, Satria Perwira<sup>2,4</sup>, Vernando Parlindungan Simanjuntak<sup>5</sup>, Sari Nur Indahty Purnamaningsih<sup>1</sup>, I Ketut Heru Suryanegara<sup>1</sup>, Desy Martha Panjaitan<sup>3</sup>, Ahmad Yudianto<sup>1</sup>**

<sup>1</sup>Departement of Forensic Medicine and Medicolegal Study, Universitas Airlangga, Surabaya, INDONESIA.

<sup>2</sup>Department of Medicine and Health, Forensic Medicine Affairs, Jambi Regional Police, INDONESIA.

<sup>3</sup>Department of Medicine and Health, Forensic Medicine Affairs, Riau Regional Police, INDONESIA.

<sup>4</sup>Faculty of Health, Universitas Almuslim, Bireun, Aceh, INDONESIA.

<sup>5</sup>Department Forensic Medicine of Landak District Hospital, West Kalimantan, INDONESIA.

## Correspondence

**Setya Aji Priyatna**

Departement of Forensic Medicine and Medicolegal Study, Universitas Airlangga, Surabaya, INDONESIA.

E-mail: ajiviny@gmail.com

## History

- Submission Date: 09-11-2024;
- Review completed: 02-12-2024;
- Accepted Date: 13-12-2024.

DOI : 10.5530/pj.2024.16.225

Article Available online

<http://www.phcogj.com/v16/i6>

## Copyright

© 2024 Phcogj.Com. This is an open-access article distributed under the terms of the Creative Commons Attribution 4.0 International license.

## ABSTRACT

The objective of forensic identification is to aid investigators in ascertaining an individual's identity. Reliability in identifying human remains from natural catastrophes, man-made disasters, and situations involving missing individuals has significantly advanced. Anthropological examination and forensic genetic profiling are particularly beneficial when traditional identification procedures, such as fingerprinting or ocular recognition, are not feasible. Even in cases where only skeletal remains are present, anthropological inquiries and forensic genetic examination of the remaining body parts can ascertain the identity and familial connection of the surviving individual. We have found a decapitated skull that is missing its lower jaw and comprises several cervical bones. Investigators think that the decapitated head is a component of a victim who was previously interred. We conducted an autopsy, an anthropological analysis and report the process of identifying skull bone mutilations in murder victims using forensic medicine, anthropology, and DNA genotyping approaches. We performed autopsy and anthropological investigations to collect data from the skeletal remains and a genetic analysis by collecting tooth and blood samples from victims' parents. These samples were then utilized for DNA extraction, calculation of DNA rate and purity, amplification, and identification of genotype. After investigation, we discovered a single cranial bone and four cervical bones. Under macroscopic examination, the bones exhibit a striking resemblance to the structure of a human head and neck. The presence of tissue still attached to the bones indicates that the time of death exceeds 10 days. The complete destruction of the cranial bones indicates that they belong to individuals aged between 21 and 39 years. The presence of shovel-shaped teeth, a rounded palatal form, straight palatal sutures, and molar teeth with four cusps provide strong identification of the deceased individual as belonging to the Mongoloid race. The assessment of height is challenging due to the absence lengthy bones

**Keyword:** Anthropology, Autopsy, Genetic Profiling, Identification, Skeletal Remains.

## INTRODUCTION

The objective of forensic identification is to aid investigators in ascertaining an individual's identity.<sup>1</sup> Significant advancements have been achieved in reliably identifying human remains from natural catastrophes, man-made disasters, and situations involving missing individuals.<sup>2</sup> Anthropological examination and forensic genetic profiling are particularly beneficial when traditional identification procedures such as fingerprinting or ocular recognition are not feasible. Even in cases when only skeletal remains are present, anthropological inquiries and forensic genetic examination of the remaining body parts can ascertain the identify and familial connection of the surviving individual.<sup>3</sup>

We have found a decapitated skull that is missing its lower jaw and comprises several cervical bones. Investigators think that the decapitated head is a component of a victim who was previously interred. A decapitated human corpse was found one week ago. The Mobile Automatic Multi Biometric Identification System (MAMBIS) technology effectively recognized the deceased individual at the location of the crime. Subsequently, his family interred the deceased's remains, adamantly

declining to conduct an autopsy. We conducted an analysis of the head parts.

## METHODS

We conducted an autopsy, an anthropological analysis, and a DNA profiling investigation. We performed autopsy and anthropological investigations to collect data from the skeletal remains. This involved ascertaining the human provenance of the skull, establishing whether it came from a single individual or several individuals, calculating the time since death, defining the gender, finding any indications of violence, diagnosing the reason of death, and determining the manner of death. We performed a genetic analysis by collecting tooth and blood samples from the alleged parents of the victim (Table 1). These samples were then utilized for DNA extraction, calculation of DNA rate and purity, amplification, and identification of genotype.

## Extraction of DNA

The three samples were obtained by utilizing the 5% chelex procedure, which involves combining 5 grams of chelex with 100 ml of a pH 8.0 TE buffer solution. The TE Buffer Solution is prepared by dissolving 0.61 g of Tris Base and 0.0186 g of EDTA in 500 ml of ddH<sub>2</sub>O. Subsequently, introduce the

**Cite this article:** Priyatna SA, Perwira S, Simanjuntak VP, Purnamaningsih SNI, Suryanegara IKH, Panjaitan DM, Yudianto A. Identification of Murder Victims' Cranial Bone Mutilation Using Forensic Medicine, Anthropology, and Genotype DNA Approaches. *Pharmacogn J.* 2024;16(6): 1404-1407.

mixed solution into either a 1 M HCL or 1 M NaOH solution until the pH of the resulting solution reaches 8.0. Prior to usage, thoroughly mix the 5% chelex to ensure that there are no residual deposits in the solution. For sample X1, include 400 µl of Chelex 5%, 2 µl of prot K with a concentration of 10 mg/ml, and 18 µl of DTT with a concentration of 0.05M. Meanwhile, samples X2 and X3 introduced 400 µl of Chalex 5% and 10 µl of Prot K 10 mg/ml into the sample tube. The X1 sample tubes were subjected to incubation in a water bath with shaking at a temperature of 56.0 °C for a duration of 4 hours, while the X2 and X3 sample tubes were incubated for 1 hour. Subsequently, we subjected each sample to vortexing for a duration of 10 seconds and centrifugation at a speed of 13,000 revolutions per minute for a period of 3 minutes. The supernatants obtained from the tubes were transferred into individual 15-ml tubes and kept at a temperature of 40 °C for further analysis.

### Quantification of DNA

0.5 µl of human standard primer, 12.5 µl of PCR reaction from the ABI Human Quantifier kit from Applied Biosystems in the USA, and 2 µl of sample were added to a 96-well plate also made by Applied Biosystems in the USA. Subsequently, we sealed the plate, subjected it to vortexing, and spun it at a speed of 3,000 revolutions per minute for a duration of 1 minute. We performed DNA quantification by placing the sample plate into the ABI 7,500 Real-Time PCR machine manufactured by Applied Biosystems in the United States.

### DNA amplification

This study involves the amplification of DNA samples using a combination of 21 microsatellite encoding markers, one Y-chromosome encoding marker, one Y-indel marker, and one sex marker (Amelogenin). These markers are put together in the GlobalFiler® kit, which is manufactured by Applied Biosystems in the United States. Table 1. The PCR tube was filled with 7.5 µl of matrix nix, 2.5 µl of forward and reverse primer pairs, and 1 ng of the extracted DNA sample. Subsequently, we introduced the PCR tube, which held the sample, into the GeneAmp PCR System 9700 manufactured by Applied Biosystems in the United States. The machine's amplification process consists of many phases. It begins with an initial heating step at a temperature of 95°C for a duration of 1 minute. This is followed by 96 cycles, each consisting of denaturation at 94°C for 10 seconds, attachment at 59°C for 90 seconds, extension at 60°C for 10 minutes, and a final extension step at 4°C for a period of 24 hours.

### Microsatellites

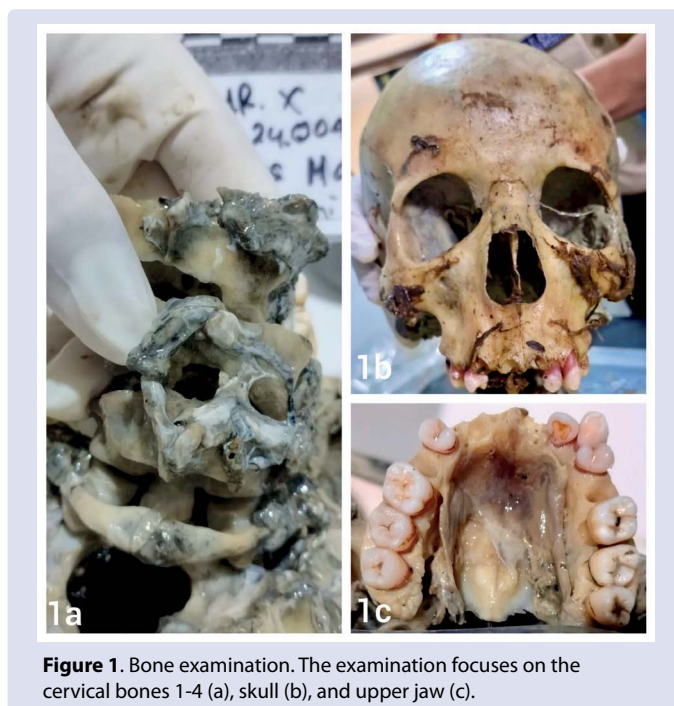
We loaded a 96-well plate (Applied Biosystem, USA) with a combined volume of 9.6 liters of HiDi formamide, 0.4 liters of 600 LIZ, and 1 liter of PCR samples. Subsequently, we hermetically closed the plate and subjected it to centrifugation at a speed of 3,000 revolutions per minute for a duration of 1 minute. The sample was subjected to a temperature of 950 °C for a duration of 3 minutes, followed by a further cooling process in a freezer at -250 °C for 3 minutes. The samples were subsequently evaluated using the ABI 3500XL Genetic Analyzer, manufactured by Applied Biosystems in the United States.

### Genotype Identification

The data obtained from the ABI 3500XL Genetic Analyzer (Applied Biosystems, USA) was processed using GeneMapper® ID-X Software v1.4 (Applied Biosystems, USA)

**Table 1. Evidence data on the discovery of an unidentified head bone.**

No	Type of Evidence	Lab Code	Information
1.	Teeth	24058_1	X1
2.	Mother's blood sample	24058_2	X2
3.	Father's blood sample	24058_3	X3



**Figure 1.** Bone examination. The examination focuses on the cervical bones 1-4 (a), skull (b), and upper jaw (c).

## RESULTS

### Autopsy and Anthropologic Findings

After careful investigation, we discovered a single cranial bone and four cervical bones. Under macroscopic examination, the bones exhibit a striking resemblance to the structure of a human head and neck (Figure 1). They originate from a singular individual. The presence of tissue still attached to the bones indicates that the time of death exceeds 10 days. Furthermore, the anatomical features suggest a male gender, as evidenced by the sloping shape of the forehead bone, the protrusion of the glabella, the roughly square shape of the orbital cavity, and the noticeable prominence of the external occipital protuberance. The complete destruction of the cranial bones indicates that they belong to individuals aged between 21 and 39 years. The presence of shovel-shaped teeth, a rounded palatal form, straight palatal sutures, and molar teeth with four cusps provide strong identification of the deceased individual as belonging to the Mongoloid race. The assessment of height is challenging due to the absence of lengthy bones. However, there were indications of violence, such as blood seepage at the back of the head and the base of the 4th cervical vertebrae. The cause of death was determined to be a sharp force applied to the neck, and the mode of death was classified as unnatural.

### DNA Findings

DNA examination showed the following results. The DNA profile labeled as 24058\_1 is a partial match to the DNA profile labeled as 24058\_2, indicating that X2 is the biological offspring of the X1. The DNA profile 14058\_1, which is half of lab code 24008\_3, confirms that X3 is the biological of X1. The paternal index is 1: 408.064,538, indicating a 99.999% probability (Table 2).

## DISCUSSION

Identifying human remains is crucial for both legal and humanitarian purposes.<sup>4</sup> The forensic identification of human remains is a legal process where the jurisdictional authority confirms the identity of the deceased by comparing information on missing individuals with the characteristics of the unidentified remains. This confirmation is officially documented by the authority's signature on a death certificate.

**Table 2. Comparison of the victim's DNA profile with the alleged victim's parents.**

Lab Code	D8S1179		D21S11		D7S820		CSF1PO		D3S1358		TH01		D13S317		D16s539	
24058_1	12	13	29	30.2	8	8	11	11	16	17	6	9	9	11	10	13
24058_2	11	12	29	30.2	8	11	10	11	16	17	6	9	10	11	11	13
24058_3	13	15	29	31	8	8	11	12	15	16	7	9	9	14	10	11
<b>Lab Code</b>	D2S1338		D19S433		vWA		TPOX		D18S51		AMEL		D5S818		FGA	
24058_1	16	20	13	14	17	18	8	11	15	20	X	Y	10	10	27	27
24058_2	16	24	14	14.2	17	17	8	11	15	20	X	X	9	10	20	27
24058_3	18	20	13	14.2	17	18	8	11	15	15	X	Y	10	12	22	27
<b>Lab Code</b>	D2S441		D22S1045		SE33		D10S1248		D1S1656		D12S391		DYS391		Yindel	
24058_1	12	14	11	15	26.2	33.2	14	15	13	14	18	20	11		1	
24058_2	12	12	15	16	28.2	33.2	13	15	14	16	19	20	-		-	
24058_3	14	14	11	17	26.2	28.2	13	14	13	15.3	18	20	11		1	

Identification necessitates a comprehensive strategy that takes into account all accessible scientific and contextual information.<sup>5</sup> In this instance, we employed a forensic medicine technique known as an autopsy, along with a forensic anthropology method involving visual examination of the bones and determine if they conform to human anatomy based on their size, shape, and bony characteristics. In addition, a DNA analysis was conducted.

The field of medicine acknowledges the autopsy as an essential component.<sup>6</sup> In addition to determining the definitive diagnosis, the autopsy establishes the relationship between the cause of death and the accompanying disorders, elucidating the interplay between the two.<sup>7</sup> Autopsies may be classified into two primary categories: forensic autopsies and clinical autopsies. The initial kind of autopsy is conducted in instances involving suspicious, violent, or unexplained reasons of death. The pathologist conducts the second procedure in the hospital, with the permission of the deceased's closest living relative, in order to ascertain and obtain a more comprehensive comprehension of the underlying factors contributing to the individual's demise. An autopsy is a postmortem examination conducted to ascertain the origin, method, and presence of sickness or damage in a deceased corpse.<sup>8</sup> In this instance, there was blood infiltration across the majority of the posterior region of the skull, along with evidence of severe force applied to the 4th cervical vertebra. This evidence suggests that the demise of the deceased was not a result of natural causes, but rather points to the possibility of a deliberate act of murder.

The fundamental goal of doing forensic anthropological analysis in a medicolegal setting is to establish a conclusive scientific identification of human remains. Anthropological work encompasses several tasks that aid in narrowing down the search for missing individuals. These tasks include searching for and recovering remains, identifying the species, assessing the sex, determining the age at death, measuring the stature, calculating the time since death, determining the ancestry, and identifying unique anatomical features.<sup>9</sup> Our identification of the skull was successful. It belonged to a male individual of the Mongoloid race, aged between 21 and 39 years. The head and neck exhibited indications of physical aggression, indicating a time of demise exceeding 10 days. This information confirms the discovery of a decapitated corpse that occurred one week earlier.

Forensic DNA analysis refers to the methodical study and interpretation of genetic material with the purpose of identifying a perpetrator or victim, particularly in criminal investigations. Forensic DNA analysis involves the use of scientific techniques to extract, purify, and examine DNA derived from biological samples collected from suspects, victims, and crime scenes. The analysis can employ various approaches, such as DNA sequencing, polymerase chain reaction (PCR), and STR (short tandem repeat) analysis. The potential categories of specimens include blood, tissue, bones, saliva, semen, hair, and several other biological

fluids.<sup>10</sup> For this example, we obtained a DNA sample from the maxillary first premolar. Additionally, we obtained blood samples from both parents for comparison. The DNA test results concluded that X1 was the biological child of X2 and X3. Thus, science has proven that the found head bone is an integral part of a buried headless body.

## CONCLUSION

Forensic medical examination, anthropology, and genetic profiling play a crucial part in both identifying victims and determining the cause of death. Autopsy and anthropological analysis can ascertain an individual's distinctive profile in this scenario. Subsequently, a genetic profile, obtained both directly and indirectly, can be employed to establish the identity of the discovered skull bones.

## ETHICS APPROVAL

The Ethical approval statement should be provided including the consent. If not appropriate, authors should state: "Not required."

## ACKNOWLEDGMENTS

Acknowledgements should be placed at the end of the article before the references. List here those individuals who provided help during the research such as providing language help, writing assistance or proof reading the article and others.

## COMPETING INTERESTS

All the authors declare that there are no conflicts of interest.

## FUNDING

This study received no external funding.

## UNDERLYING DATA

Derived data supporting the findings of this study are available from the corresponding author on request.

## REFERENCES

1. Parinduri AG. Identifikasi Tulang Belulang. Dep Forensik Fak Kedokt Univ Muhammadiyah Sumatera Utara [Internet]. 2018;1(1):1–13. Available from: <http://jurnal.umsu.ac.id/index.php/AMJ/index>
2. Ubelaker DH. International Advances in Identification of Human Remains. New Perspectives in Forensic Human Skeletal Identification. 2018 Jan 1;295–300.
3. Mushumba H, Krebs O, Jopp-Van Well E, Nzabimana D, Augustin C, Spherhake J, et al. Forensic Anthtopological Examination And DNA Analysis In The Identification Of Human Remains In Rwanda. Rwanda Medical Journal / Revue Médicale Rwandaise RMJ. 2016;73(1).

- Dahal A, Dennis Mcnevin J, Chikhani M, Ward J. An interdisciplinary forensic approach for human remains identification and missing persons investigations. *Wiley Interdisciplinary Reviews: Forensic Science* [Internet]. 2023 Jul 1 [cited 2024 Jul 21];5(4):e1484. Available from: <https://onlinelibrary.wiley.com/doi/full/10.1002/wfs2.1484>
- Semma Tamayo A. Missing Persons and Unidentified Human Remains: The Perspective from Armed Conflict Victims Exhumed in Granada, Colombia. *Forensic Science International*. 2020 Dec 1;317:110529.
- Hearle P, Wong WF, Chan J. Undergraduate medical student perspectives on the role of autopsy in medical education. *Acad Pathol* [Internet]. 2023;10(1):100068. Available from: <https://doi.org/10.1016/j.acpath.2022.100068>
- Buja LM, Barth RF, Krueger GR, Brodsky SV, Hunter RL. The Importance of the Autopsy in Medicine: Perspectives of Pathology Colleagues. *Acad Pathol*. 2019 Mar 10;6:2374289519834041. doi: 10.1177/2374289519834041. PMID: 30886893; PMCID: PMC6410379.
- Narang H, Singh RR, Pathak M, Chandra K. The Necessity of the Autopsy in Clinical Diagnosis. *Forensic, Leg Investig Sci*. 2021;7(1):1–6.
- Saukko P, Pollak S. Autopsy: Procedures and Standards. *Encyclopedia of Forensic and Legal Medicine: Second Edition*. 2015 Nov 4;304–10.
- Albujja MH. Microhaplotypes analysis for human identification using next-generation sequencing (NGS). *Next Generation Sequencing (NGS) Technology in DNA Analysis*. 2023 Jan 1;99–119

**Cite this article:** Priyatna SA, Perwira S, Simanjuntak VP, Purnamaningsih SNI, Suryanegara IKH, Panjaitan DM, Yudianto A. Identification of Murder Victims' Cranial Bone Mutilation Using Forensic Medicine, Anthropology, and Genotype DNA Approaches. *Pharmacogn J*. 2024;16(6): 1404-1407.