

Cerebral Vessel Rupture Leading to Sudden Death: Implications for Pharmacognosy

Farhad Moegis¹, Ahmad Yudianto^{1,2}, Renny Sumino¹

Farhad Moegis¹, Ahmad Yudianto², Renny Sumino¹

¹Department of Forensic Medicine and Medicolegal, Faculty of Medicine, Universitas Airlangga, dr. Soetomo General Hospital Surabaya, Surabaya, East Java, INDONESIA.

²Department of Forensic Science, Postgraduate School, Universitas Airlangga, Surabaya, East Java, INDONESIA.

Correspondence

Farhad Moegis

Department of Forensic Medicine and Medicolegal, Faculty of Medicine, Universitas Airlangga, dr. Soetomo General Hospital Surabaya, Surabaya, East Java, INDONESIA.

Email: Farhadforensic@gmail.com

History

- Submission Date: 18-10-2024;
- Review completed: 26-11-2024;
- Accepted Date: 03-12-2024.

DOI : 10.5530/pj.2024.16.233

Article Available online

<http://www.phcogj.com/v16/i6>

Copyright

© 2024 Phcogj.Com. This is an open-access article distributed under the terms of the Creative Commons Attribution 4.0 International license.

ABSTRACT

Sudden death is one of the situations that necessitates immediate treatment from a forensic doctor. The WHO defines sudden death as death occurring within 24 hours of the beginning of symptoms. There are three sorts of sudden death: unexpected, unwitnessed, and spontaneous. Diseases of the Central Nervous System are the third most common cause of sudden death. Ischemic stroke (blockage) and hemorrhagic stroke (bleeding) are examples of central nervous system illnesses. Hypertension (cardiovascular disease) and smoking are known risk factors for hemorrhagic stroke. In 2019, the global incidence of intracerebral hemorrhage (ICH) and subarachnoid hemorrhage (SAH) was 14.46 per 100,000 people. The case discussed in our paper is about the sudden death of a European (Ukrainian) ship captain who happened to be anchored in the waters of Gresik, East Java, who died of hemorrhagic stroke.

Keywords: sudden death, ICH, SAH, stroke, Cardiovascular disease.

INTRODUCTION

Sudden death is one of the cases that requires serious attention from a forensic doctor. The definition of sudden death according to WHO is death that occurs within 24 hours after the onset of symptoms. There are 3 types of sudden death, namely: Unexpected Death, Unwitnessed Death, and Spontaneous Death. The 3rd most common cause of sudden death is due to diseases of the Central Nervous System (CNS). While the 2nd most common is caused by respiratory diseases, and the first is due to cardiovascular disease. CNS diseases include ischemic stroke (blockage) and hemorrhagic stroke (bleeding).¹ Among the risk factors for hemorrhagic stroke are hypertension and smoking. The incidence of Intra-Cerebral Hemorrhage (ICH) and Sub-Arachnoid Hemorrhage (SAH) in the world in 2019 was 14.46 per 100,000 population. incidence.² Hemorrhagic stroke contributes to 10% to 20% of strokes each year. The percentage of hemorrhagic stroke is 8-15% in the United States, the United Kingdom, and Australia, and 18% to 24% in Japan and Korea. The incidence is about 12% to 15% of cases per 100,000 per year.³ Likewise in Europe, especially in Ukraine, stroke care has become a priority in Ukraine. Stroke mortality is higher than in most European countries. An estimated 130,000 people suffer from stroke in Ukraine each year; in-hospital mortality in 2020 was 19.76% of all stroke patients admitted; 30–40% of all patients died within the first month after stroke onset. Overall, stroke causes 13% of all deaths in Ukraine. In 2020, the in-hospital mortality rate was 15.65% (10 days) for ischemic stroke and 40.45% for hemorrhagic stroke.⁴

The aim of this study is to present the findings on a corpse that died suddenly due to hemorrhagic stroke, as proven through autopsy and pathological anatomical examination of ruptured cerebral blood vessels.

CASE PRESENTATION

On Sunday, January 7, 2024, the Chief Officer of the MV ship named Mr. B, informed that at around 14.35 WIB the chief and second officer (Mr. CM) when checking the Captain's cabin (Mr. DM) found that the captain was lying on his bed wearing clothes in the form of a shirt and shorts, because he did not respond when woken up, his body temperature was checked, on the first examination his body temperature was 27.9 degrees Celsius, and on the second examination his body temperature was 28.9 degrees Celsius, when checked his pulse was not palpable, and his body was already stiff, his hands were holding several Ukrainian-language medicines (Bioson acino / herbal sleeping pills, corvalment 100 mg / medicine for angina or severe headaches, Indap 2.5 mg: indapamide / diuretic for hypertension emergencies). This was then reported by the ship's crew to PT. Swasta. At that time the ship was anchored in the waters of Karang Jombang Gresik, Indonesia. On the same day at 19.00 WIB the body was taken care of. On Monday, January 8, 2024, Operational staff of PT. Swasta (Limited liability company) together with Ditpolairud (Republic of Indonesia Police Corps of Water and Air Police), departed from Mirah Tanjung Perak Port, Surabaya, towards Karang Jombang Gresik Waters, after arriving at the MV ship, Ditpolairud staff and investigators saw that Mr. DM's body had been moved to the ship's cooling room, then the body was taken and arrived at Mirah Tanjung Perak Port, Surabaya at around 19.00 WIB, the body was immediately moved to an ambulance and taken to a private hospital and then at 23.00 WIB was moved to Dr. Soetomo Hospital General Academic Hospital, Surabaya, Indonesia. On Tuesday, January 9, 2024, After obtaining a permit from the Ukrainian Minister of Foreign Affairs, an External Examination and Internal Examination/Autopsy were carried out on Mr. DM in the autopsy room of the Forensic Medicine and Medicolegal Installation of Dr. Soetomo Hospital General Academic Hospital, Surabaya, Indonesia.

Cite this article: Moegis F, Yudianto A, Sumino R. Cerebral Vessel Rupture Leading to Sudden Death: Implications for Pharmacognosy. Pharmacogn J. 2024;16(6): 1442-1446.

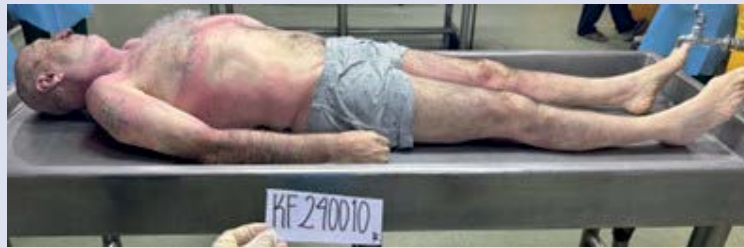

Figure 1. General signs and definite signs of death

- a. The corpse is male, aged between 60 - 70 years, body length 179 cm, body weight 90 kg, white skin color, overweight status.
- b. On the upper right arm there is an abstract tattoo resembling a black "globe" as seen on figure 2. Straight hair, white, average hair length 1 cm, complete teeth impression.
- c. Livor mortis can be found on the neck, chest, back, both arms, both palms and both legs, purplish red in color that does not disappear with pressure as seen on figure.3, incomplete rigor mortis of the corpse on the upper extremities and cannot complete rigor mortis on the lower extremities.

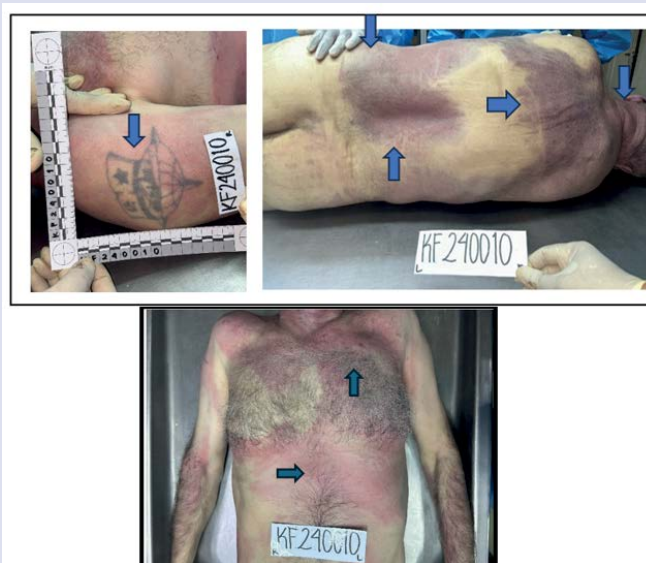

Figure 2. Signs of asphyxia:

- a. Dilation of blood vessels in the mucous membranes of the upper and lower eyelids, and in the hard membrane of the eyeball.
- b. The mucous membranes of the upper and lower lips, and gums appear bluish. (cyanosis)
- c. The tips of the fingers and nails appear bluish. (cyanosis)

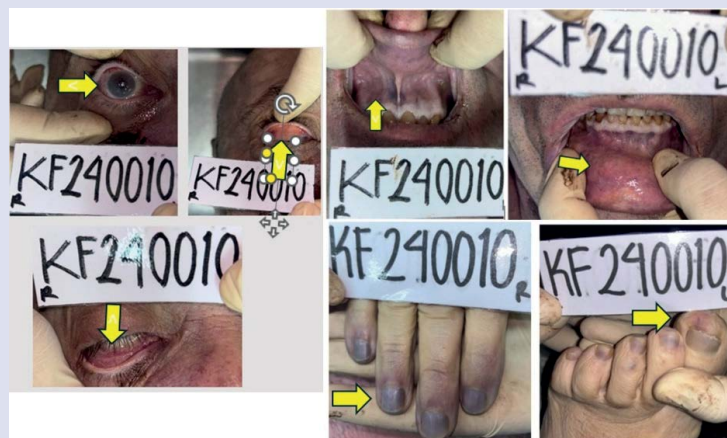

Figure 3. Internal Examination: Head:

- a. Brain: There is bleeding beneath the sub-arachnoid mater, covering the entire cerebrum, the brain weighs 1500 grams, in the section there are hemorrhage spots and blood clots.

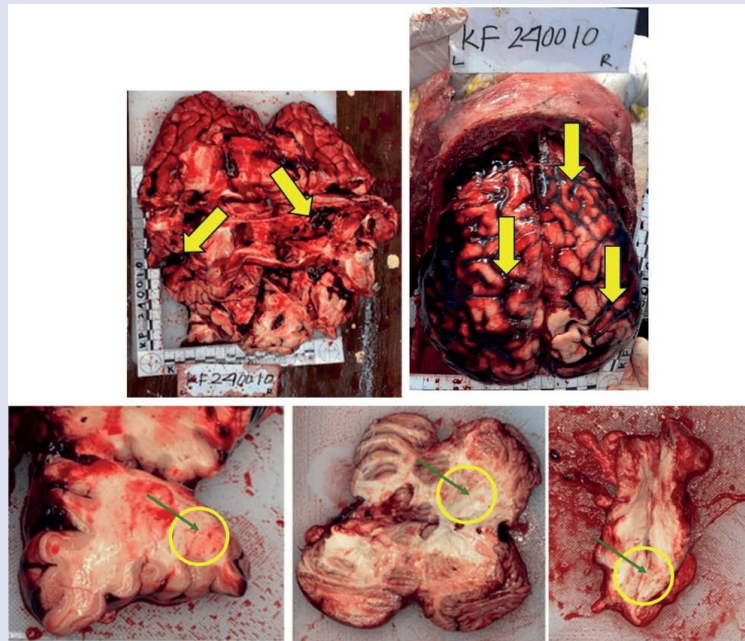


Figure 4. b. Cerebellum and brainstem: There is dilation of blood vessels. There are hemorrhage spots in the section, the cerebellum weighs 125 grams, the brainstem weighs 25 grams.

Histopathological examination of anatomy:

1. Cerebellum: Brain tissue with dilated capillary blood vessels containing erythrocytes.
2. Pancreas: Pancreatic tissue that has undergone autolysis, no inflammation is seen.
3. Right and left kidneys: Kidney tissue that has mostly undergone autolysis, with sclerosis of blood vessels.
4. Heart muscle: No atherosclerosis or myocardial infarction is seen.

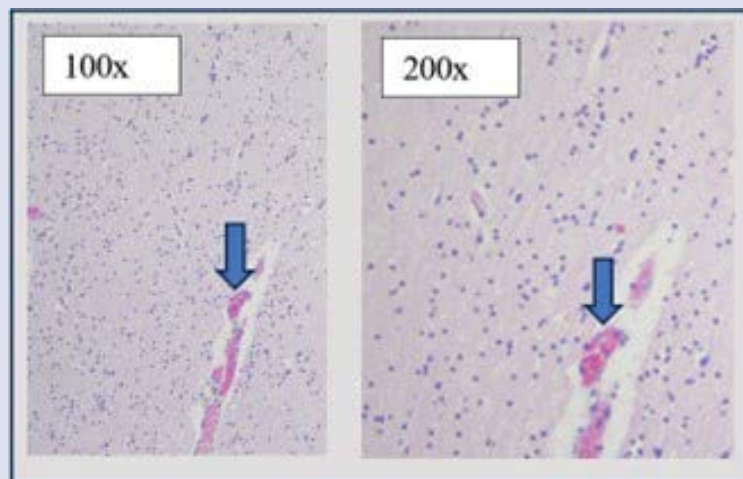


Figure 5. External and internal examination (autopsy) conclusion:

1. Cause of death: Ruptured blood vessels beneath the sub arachnoid mater
2. Mechanism of death: asphyxia

Post Mortem Interval: January 7, 2024 between 17.39 – 23.39 WIB.

DISCUSSION

Stroke, also known as apoplexy or currently better known as Cerebrovascular-Accident (CVA), is defined as the obstruction of blood flow to the brain due to blockage or rupture of one or more blood vessels in the brain (arteries) which results in death of brain tissue.^{5,6} Stroke is the 3rd leading cause of morbidity and mortality in developing countries.³ Stroke is divided into 2 types, ischemic stroke and hemorrhagic stroke. Ischemic stroke occurs more frequently, accounting for around 87%

of all strokes, while hemorrhagic stroke only occurs in 13%. Ischemic stroke is divided into 2 types, thrombotic stroke and embolic stroke. Meanwhile, hemorrhagic stroke is divided into 2 parts, namely Intracerebral hemorrhage (ICH) and Subarachnoid hemorrhage (SAH).⁵⁻⁸ As explained, hemorrhagic stroke consists of 2 types, namely; ICH and SAH. ICH often occurs suddenly and usually results in serious symptoms such as coma or even sudden death. ICH is the result of a ruptured blood vessel and bleeding into the brain parenchyma.

Sub-arachnoid hemorrhage (SAH) is bleeding that occurs under the Arachnoid membrane / Arachnoid mater or in forensics is often referred to as the brain spider membrane. SAH is divided into Non-traumatic SAH (NTSAH) and Traumatic SAH (TSAH). Non-traumatic SAH is bleeding that occurs due to the rupture of an aneurysm (bubble) of the blood vessels of the Circle of Willis (also called the Circle of Willis). It occurs 80% in the anterior part, namely in the anterior communicating artery aneurysm, however, around 10% of the ruptured aneurysm cannot be identified at autopsy because the aneurysm is too small to be seen with the naked eye or is covered by bleeding or the aneurysm may have been severely damaged at the time of the tear (rupture). Other causes of NTSAH are arteriovenous malformation (AVM), cavernous angioma, mycotic aneurysm, neoplasm (tumor), blood dyscrasia, perimecencphalic hemorrhage, and central venous thrombosis. While TSAH is SAH that occurs due to an accident or hard blow to the head the number of occurrences is small.^{3,8-10} Etiology / The most common cause of hemorrhagic stroke is High Blood Pressure (hypertension): Prolonged hypertension (HT) results in damage to the tissue that forms blood vessels (elastic lamina) and also the occurrence of fibrinoid necrosis of the subendothelium-microaneurysm (Charcot-Bouchard aneurysms), dilation of the arterioles can also occur. The most predilection of ICH caused by hypertension is in the basilar arteries, and cerebral arteries (anterior, middle, and posterior).³ In addition to ICH and SAH, there is another type of brain bleeding, namely Intraventricular hemorrhage (IVH), which is bleeding in the ventricles of the brain usually caused by; aneurysm, interventricular trauma, tumors involving the choroid plexus, and vascular malformation. Intraventricular hemorrhage (IVH) is characterized by the presence of blood in the cerebroventricular system, primarily resulting from intracerebral hemorrhage (ICH) in adults.¹¹ Other risk factors that can cause ICH are; excessive alcohol consumption, decreased LDL-Cholesterol, low serum triglycerides, anticoagulant drugs, statins, and smoking habits.¹²

Asphyxia Is an increase in carbon dioxide and a decrease in oxygen in the blood as a result of impaired gas exchange in the respiration process. Classic signs of Asphyxia (triad Asphyxia) are:

1. Injected: the occurrence of dilation of blood vessels such as in the conjunctiva due to blockages in blood vessels due to impaired blood circulation in the heart, lungs, brain, or other organs peritoneum, visceral pleura, and others.
2. Petechiae: occurs in loose tissues such as the eyelids, conjunctiva, and sclera due to rupture of the vein wall due to acute increased venous pressure. (Tardieu's spot)
3. Cyanosis: bluish discoloration of the nails, fingers, and oral mucosa (lips) due to an increase in the absolute amount of reduced Hb.¹

Asphyxia is also termed anoxia, the types of anoxia are:

1. Anoxic anoxia: Occurs when oxygen cannot enter the bloodstream or is not enough to reach the bloodstream, for example: in high places where oxygen in the air is reduced, or inhaling inert gas.
2. Stagnant circulatory anoxia: Occurs due to impaired blood circulation (such as the case in this paper).
3. Anemic anoxia: This occurs because the blood is unable to transport enough oxygen. It could be due to insufficient blood volume, or low Hb levels (in cases of CO intoxication).
4. histotoxic tissue anoxia:
 - a) Extracellular where the oxygen enzyme system is disrupted (due to HCN, barbiturates, or hypnotics).
 - b) Intracellular, namely decreased permeability of cell membranes such as in sedatives.

c) Metabolites are caused by the excretion of substances that cannot be removed (uremia or hypercapnia).

d) Substrates, namely due to lack of substances needed by the body for metabolism (eg: hypoglycemia).^{1,9,13}

Based on the ICD-X Diagnosis, the cause of death of the person was due to subarachnoid hemorrhage (I60.7) which resulted in asphyxia (R09.0).

(table 1)

CONCLUSION

Sudden death is one of the most common types of death, one of the most common causes is due to cerebral hemorrhage, as happened in the case discussed in this paper, namely in a Ukrainian ship captain who was anchored in the waters of Gresik, East Java. From the results of the external examination, it is clear that the mechanism of death of the person was asphyxia, namely the dilation of blood vessels in the mucous membrane of the upper and lower eyelids and the hard membrane of the eyeball. Then the bluish color of the oral mucosa and gums, as well as the tips of the fingers and nails of both hands and feet. These signs are proof of the occurrence of asphyxia. In the slices of the cerebrum, cerebellum, and brainstem, many and evenly distributed bleeding spots were found, these are also signs of asphyxia (stagnant circulatory anoxia) Meanwhile, the cause of death was bleeding under the cerebral spider membrane (SAH) and it was clearly seen in the autopsy results that the bleeding was extensive covering the left and right hemispheres of the cerebrum and in the slices, bleeding was found in the cerebral ventricles (IVH). This is also supported by the results of the PA examination, namely mild edema brain tissue, dilated capillary blood vessels, and containing erythrocytes.

It is suspected that the person has a history of chronic hypertension, and the use of anti-hypertensive drugs, which are supporting factors in the theory of the cause of cerebral blood vessel rupture due to hypertension which is the most common cause of cerebral blood vessel rupture and drug use.

REFERENCES

1. Yudianto A. Ilmu Kedokteran Forensik. Scopindo Media Pustaka; 2020.
2. Lim MJR, Zheng H, Zhang Z, et al. Trends in hemorrhagic stroke incidence and mortality in a National Stroke Registry of a multi-ethnic Asian population. *Eur Stroke J.* 2024;9(1):189-199. doi:10.1177/23969873231202392
3. Unnithan AKA, Das JM, Mehta P. Hemorrhagic Stroke. In: StatPearls. Treasure Island (FL): StatPearls Publishing; May 8, 2023.
4. Building a Stroke Agenda for Ukraine. World Health Organization, European Region; 2022.
5. https://www.stroke.org/-/media/Stroke-Files/Stroke-Resource-Center/Brochures/Explaining_Stroke_Brochure_2020.pdf
6. Coupland AP, Thapar A, Qureshi MI, Jenkins H, Davies AH. The definition of stroke. *J R Soc Med.* 2017;110(1):9-12. doi:10.1177/0141076816680121
7. World stroke day 2023. Kemenkes. Published October 1, 2023. Accessed May 12, 2024. <https://yankes.kemkes.go.id/read/1443/world-stroke-day-2023-greater-than-stroke-kenali-dan-kendalikan-stroke>
8. <https://www.hopkinsmedicine.org/health/conditions-and-diseases/stroke/types-of-stroke.2024>
9. Sauko P, Knight B. Accessing the E-Book Edition Knight's Forensic Pathology.; 2015.
10. Griswold DP, Fernandez L, Rubiano AM. Traumatic Subarachnoid Hemorrhage: A Scoping Review. *J Neurotrauma.* 2022;39(1-2):35-48. doi:10.1089/neu.2021.0007

11. Bu Y, Chen M, Gao T, Wang X, Li X, Gao F. Mechanisms of hydrocephalus after intraventricular haemorrhage in adults. *Stroke Vasc Neurol*. 2016;1(1):23-27. Published 2016 Feb 16. doi:10.1136/svn-2015-000003
12. Garg R, Biller J. Recent advances in spontaneous intracerebral hemorrhage. *F1000Res*. 2019;8. doi:10.12688/f1000research.16357.1
13. DiMaio VJ, Kimberley Molina D. *DiMaio's Forensic Pathology*; Third Edition.; 2022.
14. Sanicola HW, Stewart CE, Luther P, et al. Pathophysiology, Management, and Therapeutics in Subarachnoid Hemorrhage and Delayed Cerebral Ischemia: An Overview. *Pathophysiology*. 2023;30(3):420-442. doi:10.3390/pathophysiology30030032

Cite this article: Moegis F, Yudianto A, Sumino R. Cerebral Vessel Rupture Leading to Sudden Death: Implications for Pharmacognosy. *Pharmacogn J*. 2024;16(6): 1442-1446.